



**URGENT FIELD SAFETY NOTICE**  
**For 8-Channel Lead for the St. Jude Medical Infinity™ DBS (Deep Brain Stimulation) System**

UDI: 05415067020635, 05415067030306, 05415067020680, 05415067030320

26 October 2018

Dear Physician,

On October 11, 2018 Abbott began voluntarily recalling specific serial numbers associated with our 8-Channel Lead, 0.5mm spacing, for the St. Jude Medical Infinity™ DBS System that may have been impacted by an isolated manufacturing issue. As a continuation of that activity, this communication will help you identify and manage patients that may be implanted with one of these leads. *Please refer to Appendix A for the list of leads that have been implanted or not yet confirmed to be removed from your inventory.*

**Description of Issue**

A material segregation issue at our supplier may have resulted in some of the leads listed in Appendix A to contain a stimulation electrode that was manufactured with a nickel-cobalt based alloy (MP35N) instead of the specified platinum iridium. If a MP35N electrode is used for stimulation, there is a risk of corrosion.

We are currently aware of five (5) reports from three (3) centers describing that the most proximal stimulation electrode appeared less radiopaque than the more distal electrodes when radiographed. Three (3) of the five (5) leads that exhibited this anomaly are implanted, and there have been no reports of patient harm to date. Abbott tested the two (2) leads returned for investigation, and determined that the most proximal unsegmented electrode was MP35N.

Our investigation determined that up to 123 leads may have this condition. These may be dispersed within 1,767 total leads, of which 1,242 were distributed worldwide. We have initiated action to remove customer inventory in locations that were identified to have potentially affected unused leads in their possession. Inventory that is not included in Appendix A is not impacted.

For potentially affected patients implanted, further details regarding risks and patient management recommendations are included below.

**Description of Patient Risk**

If an electrode with MP35N corroded, the following risks are possible: Neurological Deficit/Dysfunction (MRI-related), unintended stimulation effects, and/or an inflammatory response, which could result in harm, including the need for acute medical/surgical intervention to replace the lead. MRI safety/compatibility may be impacted. We do not recommend MR scans on potentially affected patients until you have confirmed that MRI can be performed pursuant to the Patient Identification and Management Recommendations below.

Abbott has assessed the risk of both implantation and use of an MP35N electrode in the potentially affected patients, and has identified two separate groups:

1. **For patients that do not require stimulation through the most proximal unsegmented electrode**, which is estimated to be 93% based on an ongoing Abbott post-market DBS study, Abbott's risk assessment has concluded that an MP35N electrode that has not been used for therapeutic stimulation, and remains static, is not expected to cause patient harm, because MP35N is known to be biocompatible.
2. **For patients that require stimulation through the most proximal unsegmented electrode**, which is estimated to be 7%, stimulating through an MP35N electrode is not advised due to the risk of corrosion under charge injection. If corrosion has initiated, it is expected to continue even if stimulation is turned off on the affected electrode.

### **Patient Identification and Management Recommendations**

While not intended to serve as a substitute for your professional judgement, Abbott, in consultation with our medical advisory board, recommends the following for patients implanted with a potentially affected lead listed in Appendix A (Refer to **Appendix B** for a visual process flow diagram):

#### **Identification and Screening Process**

*For all patients who have leads listed in Appendix A*

- Review available radiographs (e.g. intraoperative fluoroscopic images, or scout X-ray on post-implant Computed Tomography (CT)) and locate the directional marker.
- If there are no available images of the lead, perform cranial X-rays (Lateral and A-P) on the patient before proceeding.
- Verify from the images that there are four electrodes with similar radiopacity to each other.
  - If the most proximal unsegmented electrode is made from MP35N, it will appear less radiopaque compared to the three distal electrodes. Refer to images in **Appendix C** for reference.

#### **Patient Management Recommendations Based on Screening Outcome**

*For patients where the radiograph appears normal*

- If the radiograph appears normal, because there is no difference in the radiopacity of the most proximal (dorsal) unsegmented electrode when compared to the more distal electrodes, the lead implanted in your patient is constructed as intended.
- Please confirm your record review using the enclosed patient acknowledgement form, and return to Abbott. **No additional action with the patient is necessary.**

*For patients where the radiograph is unclear*

- **Abbott is available to assist you in determining the presence of the issue and/or the need for additional imaging.**

*For patients where the radiograph reveals variation in radiopacity*

If the most proximal unsegmented electrode appears less radiopaque than the distal electrodes, the lead implanted in your patient does **not** have the intended construction. Please confirm your image review using the enclosed patient acknowledgement form.

1. Review available medical records and provide your Abbott representative session reports to determine the patient's programming history.

- If the MP35N electrode has not been used for therapeutic stimulation, as verified by medical records and session reports, **a lead replacement surgery is not recommended**. The presence of the MP35N electrode is not expected to cause patient harm in a static state. Abbott has determined that MRI can be performed within labeled limits.
  - If therapeutic benefit requires stimulation through the MP35N electrode, **Abbott recommends lead replacement surgery** because the overall stability of the electrode cannot be assured.  
**MRI is not recommended** for any patients that have a history of therapeutic stimulation through the affected electrode, but choose to remain implanted. In such cases, Abbott will issue a custom patient communication to include this information. This should also be updated in the patient's medical records.
  - If therapeutic benefit can be obtained through alternative programming, clinicians may still consider lead replacement. In the interim, Abbott intends to execute additional analysis that may aid in the clinician's assessment of risk, and will provide the latest information upon its availability to these physicians.  
**MRI is not recommended** for any patients that have a history of therapeutic stimulation through the affected electrode, but choose to remain implanted. In such cases, Abbott will issue a custom patient communication to include this information. This should also be updated in the patient's medical records.
2. For all patients where the lead will remain implanted, Abbott will issue a custom patient communication that advises against programming through the most proximal unsegmented electrode. This should also be updated in the patient's medical records.

A copy of this letter is available on [www.sjm.com/notices](http://www.sjm.com/notices). Should you have questions about patient management or this issue, please contact your local Abbott Representative or Abbott Support at **+46 8 474 4147 (Outside the U.S.)**.

Adverse reactions or quality problems experienced with the use of this product may be reported to your local Abbott Representative.

We sincerely apologize for any difficulties this may cause you and your patients. Abbott is committed to ensuring our customers receive the most current information available to provide optimal care for patients, and providing the highest quality products and support. We thank you for assisting us with this process.

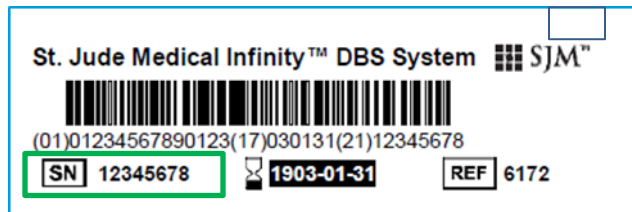
Sincerely,

Christopher Gallivan  
Divisional Vice President, Quality  
Abbott Neuromodulation

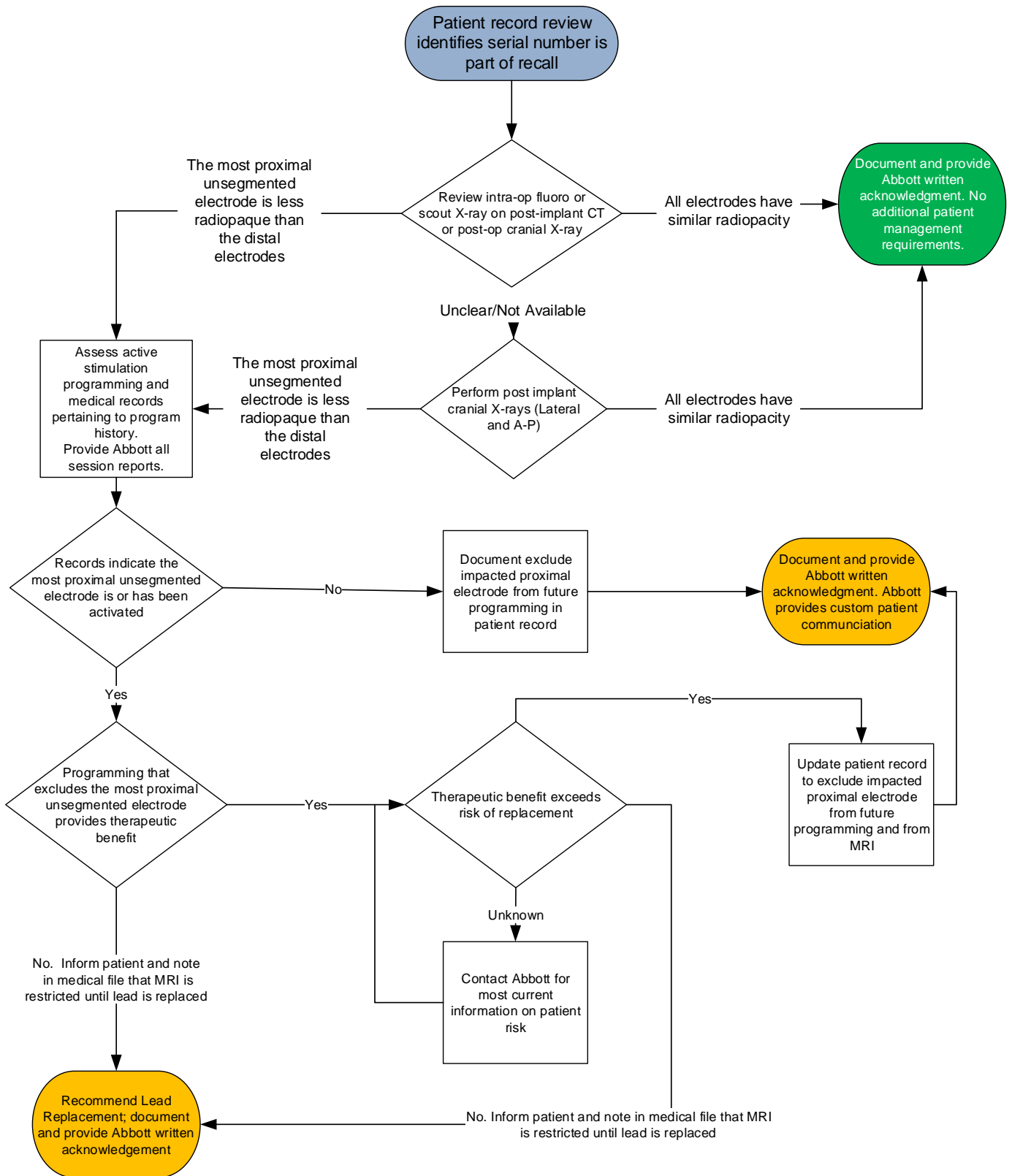
**APPENDIX A: AFFECTED LEADS**

Model no.	Serial No.	Batch	Material Description	Ship to Name
6172ANS	17086337	6197963	8CH SJM INF Lead Kit, 40cm, 0.5, Black	AL-JEEL MED.& TRAD CO LTD
6172ANS	17086342	6197963	8CH SJM INF Lead Kit, 40cm, 0.5, Black	AL-JEEL MED.& TRAD CO LTD
6172ANS	17086355	6197963	8CH SJM INF Lead Kit, 40cm, 0.5, Black	AL-JEEL MED.& TRAD CO LTD
6172ANS	17086357	6197963	8CH SJM INF Lead Kit, 40cm, 0.5, Black	AL-JEEL MED.& TRAD CO LTD
6170ANS	17145439	6244627	8CH SJM INF Lead Kit, 30cm, 0.5, Black	AL-JEEL MED.& TRAD CO LTD
6170ANS	17145459	6244627	8CH SJM INF Lead Kit, 30cm, 0.5, Black	AL-JEEL MED.& TRAD CO LTD
6170ANS	17145461	6244627	8CH SJM INF Lead Kit, 30cm, 0.5, Black	AL-JEEL MED.& TRAD CO LTD
6170ANS	17145463	6244627	8CH SJM INF Lead Kit, 30cm, 0.5, Black	AL-JEEL MED.& TRAD CO LTD

Location of Serial Number Reference: SN

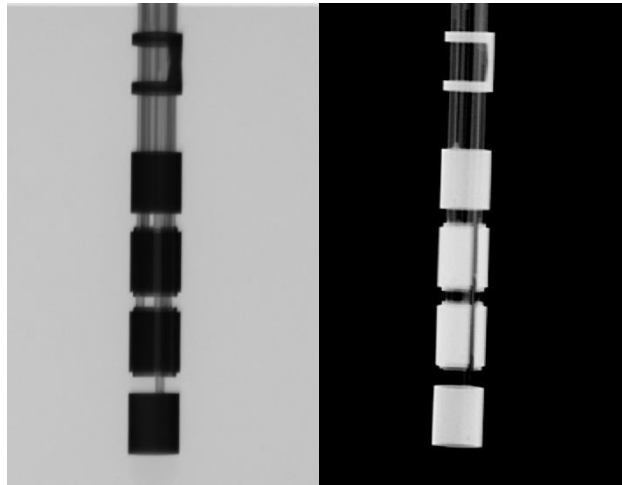


## APPENDIX B: Patient Management Flow Chart



### **APPENDIX C: Example Images**

Figure 1 shows X-ray images of the intended material construction. Alternative modalities may not have this level of resolution. Four electrodes of equal radiopacity and the placement marker should all be visible.




**Figure 1: Intended Material Construction**

The image on the left demonstrates the appearance on radiograph with greyscale inversion (i.e. fluoroscopic image) – all electrodes have similar radiopacity

The image on the right demonstrates how this may appear on cranial X-ray – all electrodes have similar radiopacity

Figure 2 shows X-ray images of the most proximal unsegmented electrode with the incorrect material construction.



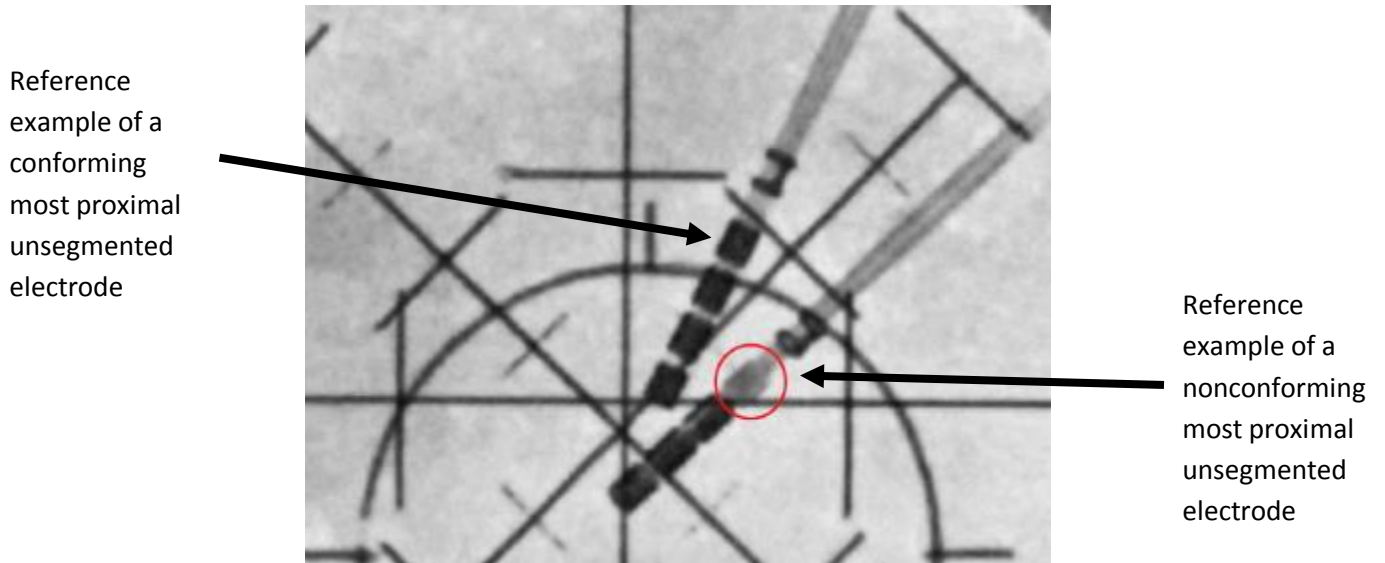
**Figure 2: Incorrect Construction Image.**

The image on the left demonstrates the appearance on radiograph with greyscale inversion (i.e. fluoroscopic

image); the distal electrodes are darker than the most proximal unsegmented electrode.

The image on the right demonstrates how this may appear on cranial X-ray, where the distal electrodes appear whiter than the most proximal unsegmented electrode

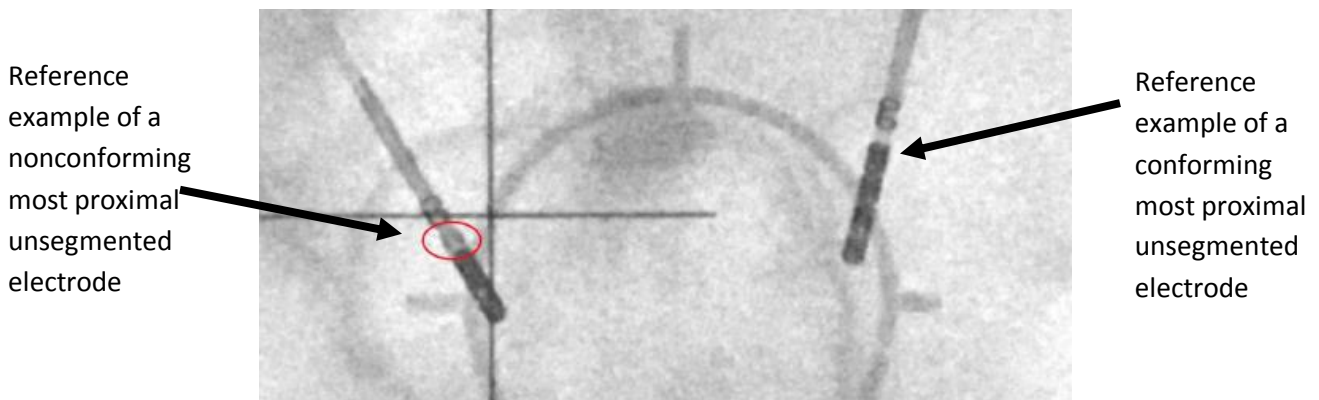
Figure 3 shows an example of a fluoroscopic lateral X-ray with a nonconforming and a conforming lead.



**Figure 3: Fluoroscopic lateral X-ray**

The circled image shows an example of a nonconforming most proximal unsegmented electrode, which appears less radiopaque by comparison to the more distal electrodes. For reference, the second lead has four electrodes with the expected appearance.

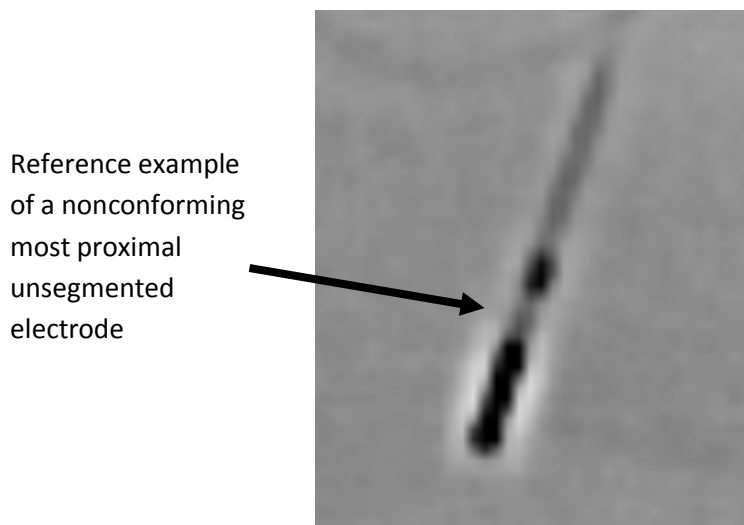
Figure 4 shows an example of a fluoroscopic Anterior Posterior X-ray of a nonconforming lead and a conforming lead



**Figure 4: Fluoroscopic Anterior Posterior X-ray**

The circled image shows an example of a nonconforming most proximal unsegmented electrode, which appears less radiopaque by comparison to the more distal electrodes. For reference, the second lead has four electrodes of similar radiopacity.

Figure 5 shows a post-operative Computed Topography (CT) scout X-ray



**Figure 5: post-operative Computed Topography (CT) scout X-ray**

The arrow points to a nonconforming most proximal unsegmented electrode, which appears less radiopaque by comparison to the more distal electrodes.