

دليل العيوب الخلقية

Birth Defects Manual

Guide des Malformations Congénitales

English Version



NCPNN

NATIONAL COLLABORATIVE PERINATAL NEONATAL NETWORK
RESEAU NATIONAL POUR LA COLLABORATION PERINATALE NEONATALE

march of dimes
Global Network
For Maternal and Infant Health



Manual on Birth Defects

Version 2, last edited February 2013
©NCPNN

Table of Contents

Introduction	4
List of abbreviations	7
Chapter I : Congenital malformations of the circulatory system	9
Chapter II : Cleft lip and cleft palate	49
Chapter III : Chromosomal Abnormalities	55
Chapter IV : Congenital malformations and deformations of the musculoskeletal system	63
Chapter V : Congenital malformations of the digestive system	80
Chapter VI : Congenital malformations of the nervous system	98
Chapter VII : Congenital malformations of the urinary system and genital organs	112
Chapter VIII: Congenital malformations of the respiratory system	124
Chapter IX : Congenital malformations of eye, ear, face and neck	130
References	140

Introduction

Birth defects remain a cause of morbidities (i.e. premature births) and mortality (stillbirths and infant death) specifically in the Middle East and North Africa (MENA) region. During the sixty-third world health assembly in 2010, the World Health Organization urged all member states to record surveillance data on birth defects as part of national health information since its recognized as a cause of stillbirths, preterm birth and neonatal mortality mostly in low and middle-income countries.

Birth defects (BD) are defined as abnormalities of structure, function, or body metabolism that are present at birth. BD include a wide range of abnormalities with varying levels of impact. These abnormalities may either lead to mental and/or physical impairments or to lethal outcomes. BD are complex diseases that can be caused by genetic, environmental, in utero exposure to medicines, drugs, chemicals or infections. However, 70 percent of birth defects remain unexplained by a known cause.

In a recent report from the March of Dimes foundation (MOD), one in every 33 babies born in the United States has some kind of birth defect. There are more than 4,000 different known birth defects, ranging from minor to serious malformations. Many of the identified birth defects are preventable or their outcomes can be improved by early identification at birth and treatment. Although many can be treated or cured, BD are the leading cause of death in the first year of life, accounting for more than 20% of all infant deaths. Babies born with birth defects have a greater chance of illness and long term disability than babies without birth defects, in addition to a lifetime financial burden. In 1992, it was estimated that the total lifetime cost for caring for children with birth defects in the United States exceeded \$ 1.4

billion dollars annually. Because of the heavy burden of BD, the Centers for Disease Control and prevention (CDC) recommends establishing a surveillance system for BD which is vital for monitoring, detecting trends and disseminating the information to study their causes.

According to the March of Dimes global report (2006), 94% of serious BD occur in low and middle-income countries with the majority being reported from the Middle East and North Africa (MENA) region. Lebanon lacks surveillance systems for identifying birth defects (BD) despite the evidence of the health burden caused by these defects and the exposure to various risk factors in the country. However, the National Collaborative Perinatal Neonatal Network (NCPNN) established in 1998 a database of perinatal information collected from currently 31 hospitals located in different regions of the country and representing about 30% of the total national births population.

Based on the above, the Ministry of Public Health (MOPH) in Lebanon launched a national surveillance program for birth defects with the technical expertise of the NCPNN team and the support of the CDC. Implementation of this national surveillance is a milestone for the country and major achievement especially in a context where serious birth defects are thought to be occurring. Understanding the toll of birth defects and associated risk factors would lead to implement interventions to prevent those defects but also to improve care of affected newborns.

Data collected over the past ten years by the NCPNN, revealed significant underreporting of BD. The overall prevalence of birth defects (BD) reported were ranges between 82 per 1,000 live births in low-income regions and 39.7 per 1,000 live births in high-income regions. However, the rate of birth defects in Lebanon, as reported by the NCPNN for all types of malformations (minor and major) was 32.3

per 1,000 live births in 2007 and 16.5 per 1,000 live births in 2009 when accounting for only major malformations. In addition, data collected by the NCPNN from September 2003 to December 2005 unexpectedly indicated that newborns with congenital malformations are more reported from hospitals in urban areas (66.2%) compared to rural and underserved areas (33.8%) with lower socioeconomic status and higher rates of consanguinity.

Our analysis led to the conclusion that one of the main reasons is BD underreporting. This observation is most likely due to poor expertise, lack of training and equipments, unavailability of specialists at all times and lack of regional referral systems at these centers.

Thus, with the support of the MOD and the CDC, the NCPNN developed this BD manual as an initiative to train personnel in order to improve on BD recognition, diagnosis and reporting of BD to the newly established national surveillance. This manual is a work in progress and this first edition will include the most common BD encountered in our population based on our experience for the past fourteen years. Corresponding interactive CD will follow later on. BD will be classified in this manual according to the International Classification of Diseases 10th Revision (ICD-10) and will be divided by systems. Since this is an educational manual addressed to care givers from various backgrounds and educational levels (research assistants, registered nurses, general physicians), it is intentionally simplified and summarized. Should the reader need more detailed information, a list of reference books and website resources is included.

We would like to acknowledge all the individuals who contributed to the development of this manual as well as all the doctors who shared their patient's pictures with us.

Authors:

Charafeddine Lama, MD

El Rafei Reem, MSc

Farra Chantal, MD

Romani Diala, MD

Yunis Khalid, MD

Contributors:

Abou Chebel Naji, MD

Azizi Sophie, MSc

Badran Maya, BSc

Bejjany Rachelle, MPH

Choueiry Nathalie, MSc

Dabbagh Omar, MD

Ghafari Joseph, MD

Hamadeh Hanine, BS

Nakad Pascale, BS

Sakati Nadia, MD

Soubra Maher, MD

Wehbe Mira, MPH

List of abbreviations

AS: aortic stenosis
ASD: Atrial Septal Defect
AV: Atrioventricular
BD: Birth Defects
CDC: Centers for Disease Control and prevention
CNS: central nervous system
CT: Computed tomography
DH: diaphragmatic hernia
D-TGA: dextro transposition of great arteries
GI: gastrointestinal
HLHS: hypoplastic Left Heart Syndrome
ICD-10: International Classification of Diseases 10th Revision
KUB: kidney, ureters and bladder Xray
LVOTO: left ventricular outflow tract obstruction
M:F ratio: ratio male female
MENA: Middle East and North Africa
MI: mitral insufficiency
MOD: March of Dimes foundation
MOPH: Ministry of Public Health
MRI: Magnetic resonance imaging
MSAFP: maternal serum alpha-fetoprotein
NCPNN: National Collaborative Perinatal Neonatal Network
NOS: not specific
PDA: Patent ductus arteriosus
PFO: patent foramen ovale
TEF: tracheoesophageal fistula
TGA: transposition of great arteries
TOF: Tetralogy of Fallot
T13: Trisomy 13
T18: Trisomy 18
T21: Trisomy 21
VSD: ventricular septal defect
US: ultrasonography

Chapter I: Congenital malformations of the circulatory system

In this section:

- I. Introduction
- I.1. Atrial Septal Defect
- I.2. Common Atrioventricular canal
- I.3. Coarctation of the aorta
- I.4. Discordant ventriculoarterial connection
- I.5. Hypoplastic Left Heart Syndrome
- I.6. Malformations of the aortic & mitral valves
- I.7. Malformations of the pulmonary & tricuspid valves
- I.8. Congenital pulmonary valve stenosis
- I.9. Single Ventricle
- I.10. Tetralogy of Fallot
- I.11. Ventricular Septal Defect

I. Introduction:¹⁻⁵

- Congenital heart diseases include defects of the heart and circulatory system.
- They are the most common type of birth defects: 4 to 8 per 1000 live birth.
- They can be asymptomatic at birth and range from mildly severe to life threatening conditions.
- In 90% of the cases the etiology is multifactorial.
- In 10% the etiology can be related to drugs used during pregnancy (i.e. warfarin, diphenylhydantoin) or intra-uterine infections (i.e. Rubella).
- The risk is higher in newborns with genetic abnormalities (i.e. trisomy 21, 18 and 13).
- Clinical presentation vary from asymptomatic to cardiac failure:
 - tachypnea
 - desaturation events
 - cyanosis
 - heart murmur
 - feeding difficulties
 - failure to thrive
 - cardiogenic shock
- Diagnostic tools or tests to perform:
 - Chest X-ray
 - Electrocardiogram
 - Echocardiogram
 - Cardiac catheterization occasionally needed
 - Cardiac magnetic resonance imaging (MRI) / Computed tomography (CT) rarely needed
 - Referral to a tertiary care center where pediatric cardiology and cardiothoracic surgery are available is essential in most cases.

I.1. Atrial Septal Defect (ASD)

- Description: Called also ostium secundum. ASD is relatively common and frequently occur in isolation. It represents about 6-10% of all cardiac anomalies it is more frequent in females (M:F ratio 1:2). ASD is characterized by the presence of one or several openings of variable sizes in the atrial septum, the muscular and fibrous wall between the right and left atria these openings allow mixing of oxygenated and non-oxygenated blood. ASD may close spontaneously otherwise it may require surgical treatment.
- Symptoms:
 - Most ASD are asymptomatic and go undetected
 - They may first present at 6-8weeks of age :
 - Heart murmur that is soft systolic with “fixed” splitting of the second heart sound
 - Cyanosis may occur if blood is diverted from the inferior vena cava across the ASD
- Other associated anomalies:
 - Down Syndrome Ebstein's anomaly
 - Holt–Oram syndrome
 - Lutembacher's syndrome

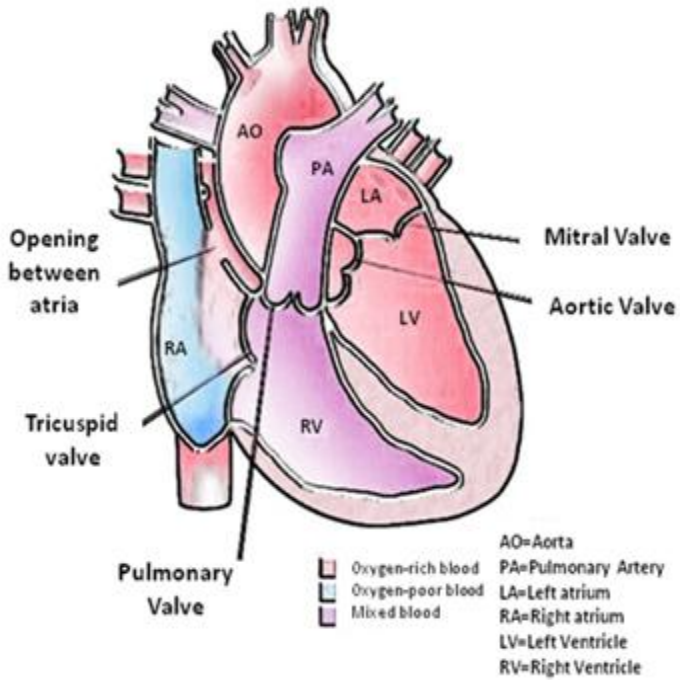


Figure 1.1 Atrial Septal Defect

I.2. Common Atrioventricular canal

- Description: Atrioventricular (AV) septal defects account for 4-5% of all congenital heart defects. The complete form is characterized by a common opening between all four heart chambers with:
 - A large septal defect between the right and left atriums
 - A large defect between the two ventricles
 - A common atrioventricular valve that connects both atria to the ventricles.

- Symptoms:

Signs of heart failure:

- Easy fatigability and short breath
 - Poor feeding and poor weight gain
 - Rapid heart rate
 - Pale and/or cool skin
 - Sweating
 - Cyanosis variable, may be only on exertion
 - Heart murmur, overactive heart
- Other associated anomalies:
 - Trisomy 21 (Down syndrome)
 - Asplenia syndrome
 - DiGeorge and Ellis-van Creveld syndromes in partial AV Canal form.

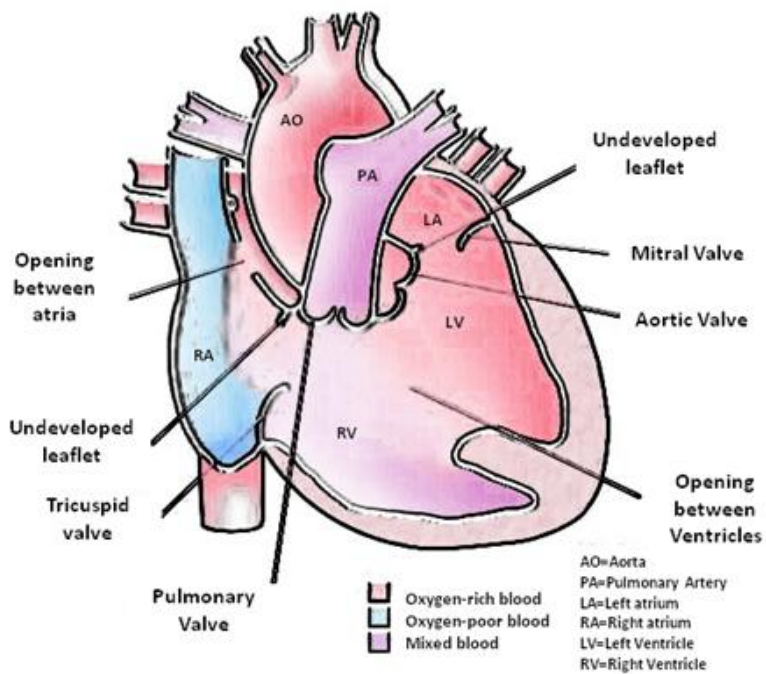


Figure 1.2 Common Atrioventricular canal

I.3. Coarctation of the Aorta

- Description: Coarctation of the aorta accounts for about 6-8% of patients with congenital heart defects. It is characterized by a localized narrowing or stenosis in the proximal thoracic aorta this leads to increased pressure in the heart during contractions resulting in hypertension or more severely congestive heart failure. It is more common in males: M:F ratio 1.5. Surgical correction is recommended even for mild defects.

- Symptoms:
 - Severity of symptoms depends on the size of the narrowing and the associated anomalies.
 - Decreased or absent lower extremity (femoral) pulses on routine physical exam.
 - Significant discrepancy in upper and lower extremities blood pressure (BP).
 - Presentation can be catastrophic at day 10 to 14 days after closure of the ductus arteriosus with acute heart failure, shock and severe acidosis:
 - Tachycardia
 - Dyspnea
 - Diaphoresis
 - Pallor
 - Irritability
 - Hepatomegaly
 - Heart murmur with hypertension in older children.

- Other associated anomalies:
 - Bicuspid aortic valve
 - Large ventricular septal defect (VSD)
 - Aortic stenosis
 - Patent ductus arteriosus (PDA)
 - Mitral stenosis
 - Turner syndrome
 - Multiple left sided obstructive lesions: Shone's syndrome

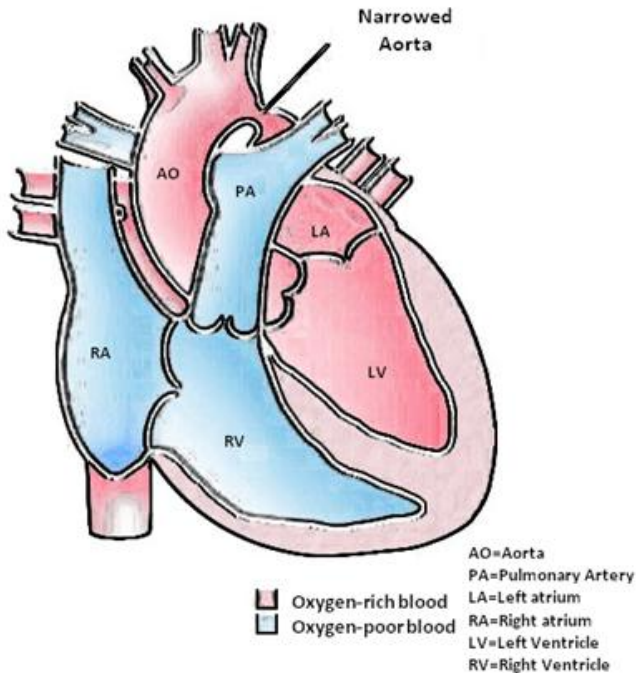


Figure 1.3 Coarctation of the Aorta

I.4. Discordant ventriculoarterial connection

a. Dextroposition of the heart

- Description:
 - Displacement of the heart to the right side of the thoracic cavity.
 - No anatomic alteration.

- Symptoms:
 - None

- Other associated anomalies:
 - Trisomy 13

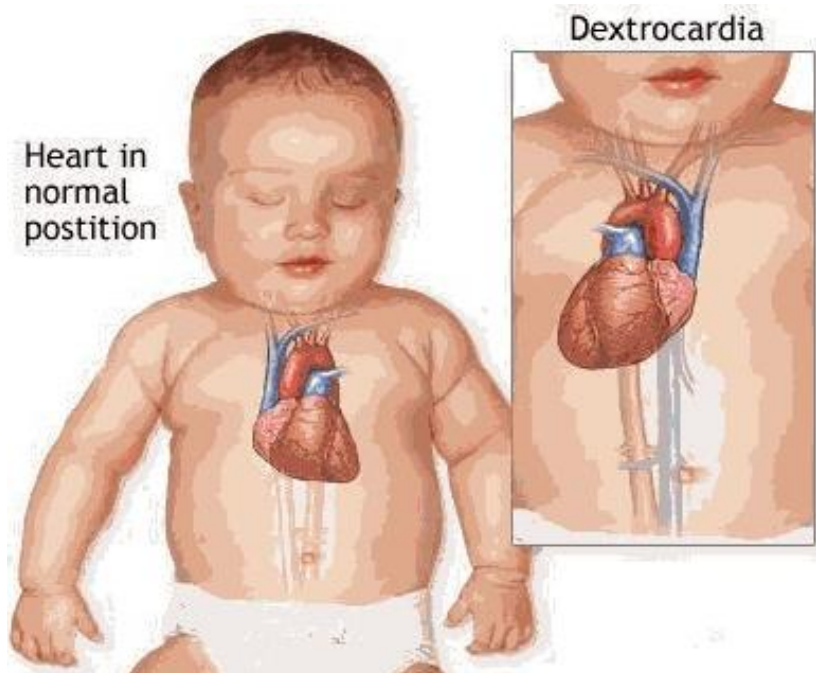


Figure 1.4a Dextraposition of the heart

b. Transposition of Great Arteries or Vessels

- Description: Prevalence is 20-30/100,000 live births, accounts for 5-7% of all congenital heart defects with a strong male predominance. Literally the term means the aorta arises from the right ventricle and the pulmonary artery from the left ventricle oxygenated blood returns to the lungs and desaturated blood returns to the systemic circulation. Complete transposition of great arteries (TGA) is the most common, also referred to as D-TGA because the aorta is anterior and to the right (dextro-) of the pulmonary artery
- Symptoms:
 - Prominent cyanosis shortly after birth if no adequate mixing between the two circulations
 - Infants with TGA and large VSD may have initially cyanosis only with crying
 - Signs of congestive heart failure develop within 2-6weeks
 - Infants with TGA, VSD and pulmonary stenosis or atresia typically have prominent cyanosis and present similar to infants with tetralogy of Fallot
- Other associated anomalies:
 - Almost always patent foramen ovale (PFO)
 - VSD in 40-45% and about 10% of those have left ventricular outflow tract obstruction (LVOTO)
 - Less common: ASD, PDA
 - Infrequent extracardiac anomalies (in about 9%)

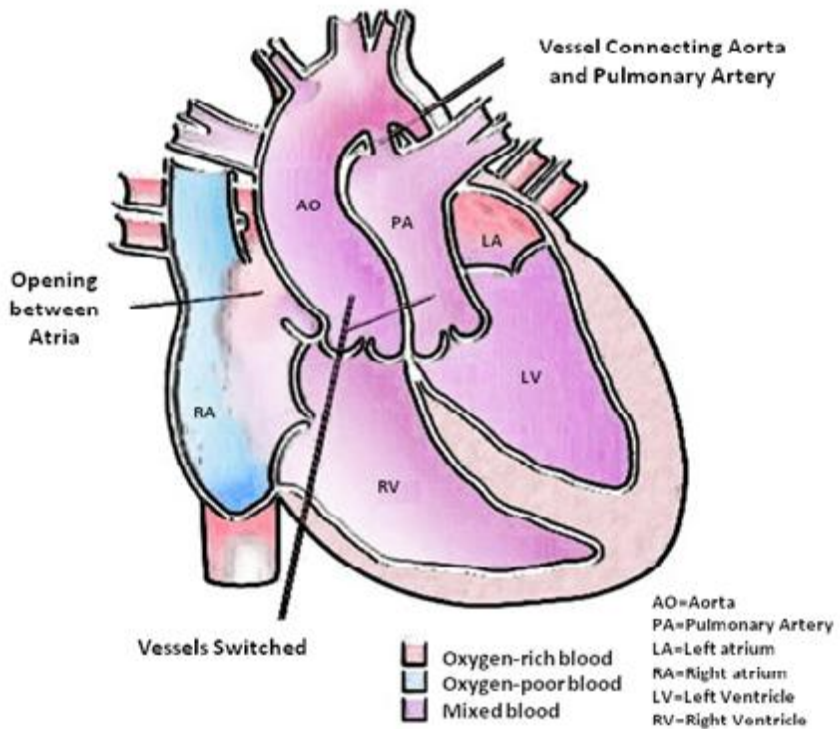


Figure 1.4b Transposition of great arteries

I.5. Hypoplastic Left Heart Syndrome (HLHS)

- Description: Hypoplastic Left Heart Syndrome (HLHS) is characterized by an underdevelopment of most of the left heart structures including:
 - aorta
 - aortic valve
 - left ventricle
 - mitral valve
 - left atrium

It represents about 8% of all congenital heart defects. Transmission is autosomal recessive and most patients are male (67%). It is usually fatal in the first month of life if not treated.

- Symptoms:
 - Cyanosis within hours or several days after birth
 - Pallor, ashen color
 - Rapid and difficulty breathing
 - Weak pulse in all extremities
 - Low blood pressure
 - Faint murmur, gallop rhythm in heart failure
 - Lethargy
 - Severe shock may result in: seizures, renal failure, liver failure and cardiac failure
- Other associated anomalies:

10% of the cases have associated extracardiac malformations.

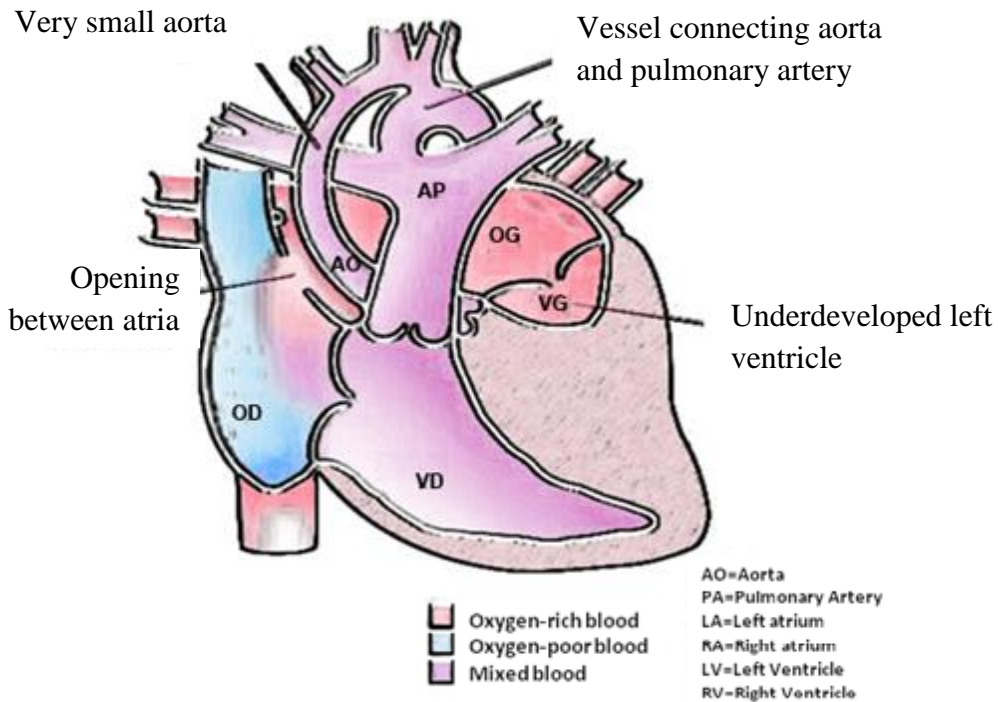


Figure 1.5 Hypoplastic Left Heart Syndrome

I.6. Malformations of the aortic & mitral valves

- Description: This group is characterized by narrowing or insufficiency of the aortic or mitral valves. It includes:
 - congenital mitral stenosis or atresia
 - congenital mitral insufficiency
 - congenital aortic valve stenosis or atresia
 - congenital aortic valve insufficiency

a. Congenital mitral stenosis or atresia

- Description: Mitral atresia is defined as the absence of the left AV connection. It is often seen in conjunction with complex single ventricle anatomy. Mitral stenosis is a continuous spectrum of malformations involving several components of the mitral valve.
- Symptoms:
 - Depend on the degree of obstruction
 - May be asymptomatic at birth
 - In case of severe stenosis symptoms are those of diminished peripheral perfusion due to low cardiac output and right heart failure
- Other associated anomalies with mitral atresia:
 - Double outlet right ventricle
 - Single left ventricle with transposition of the great vessels

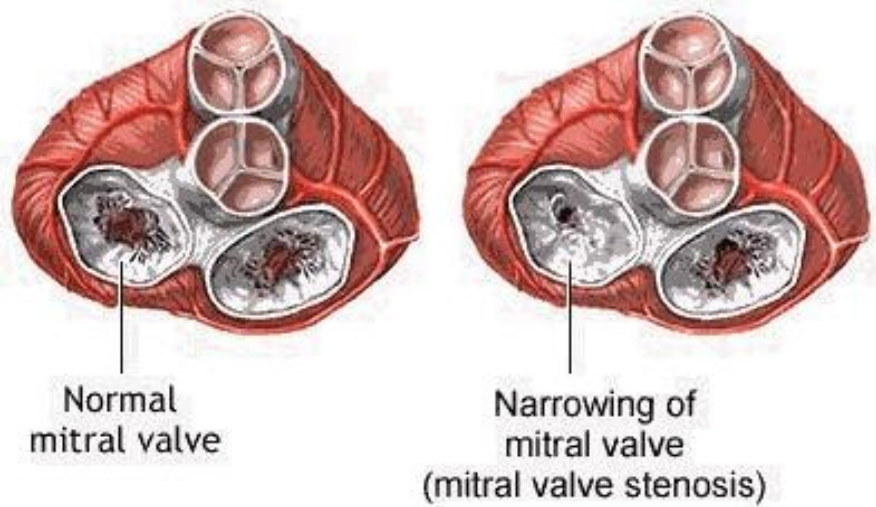


Figure 1.6a Congenital mitral stenosis

b. Congenital mitral insufficiency (MI)

- Description: Isolated congenital mitral insufficiency (MI) is rare. It is the result of abnormalities in the valve leading to mitral regurgitation (backflow of blood to the left atrium)

- Symptoms:
 - Depend on the degree of valve incompetence or insufficiency
 - Most are asymptomatic at birth
 - Signs of mitral insufficiency gradually appear as the left atrium enlarges and the left ventricle volume increases

- Other associated anomalies:
 - Atrial septal defect
 - Ventricular septal defect
 - Transposition of the great vessels

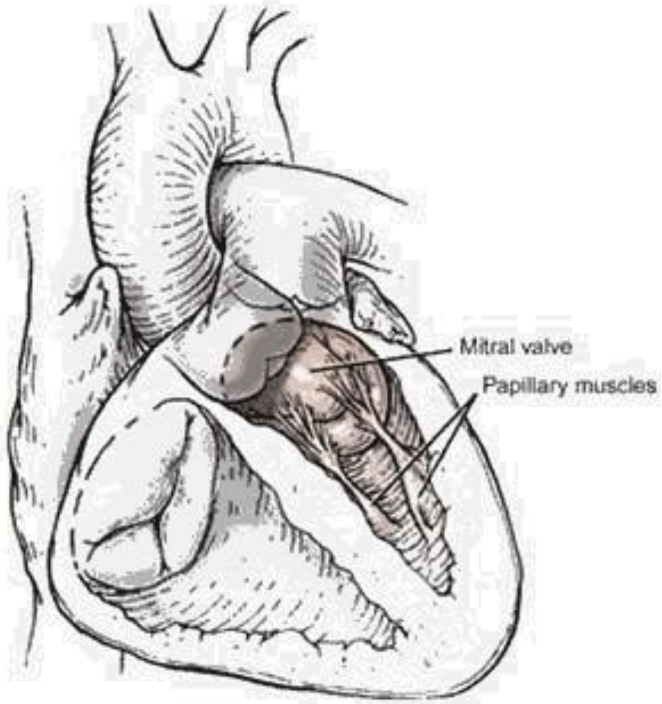


Figure 1.6b Congenital mitral insufficiency

c. Congenital aortic valve stenosis or atresia

- **Description:** It is characterized by either incomplete opening of the aortic valve (stenosis) or the absence of the aortic valve (atresia). These abnormalities cause obstruction to the ejection of blood from the left ventricle. Valvar aortic stenosis (AS) occurs in 3-6% of all patients with congenital cardiovascular defects. Valvar AS is more common in males M:F ratio 4:1.

- **Symptoms:**
 - May be asymptomatic in cases of mild stenosis
 - Infants with critical or severe valvar aortic stenosis are irritable, pale, hypotensive or may present with heart failure:
 - Dyspnea
 - Tachypnea
 - Subcostal retractions
 - Diffuse rales
 - Cyanosis, secondary to pulmonary venous unsaturation

- **Other associated anomalies:**
 - Turner syndrome (XO)
 - Coarctation of the aorta
 - Patent ductus arteriosus
 - N.B: Supravalvar aortic stenosis associated with William's syndrome

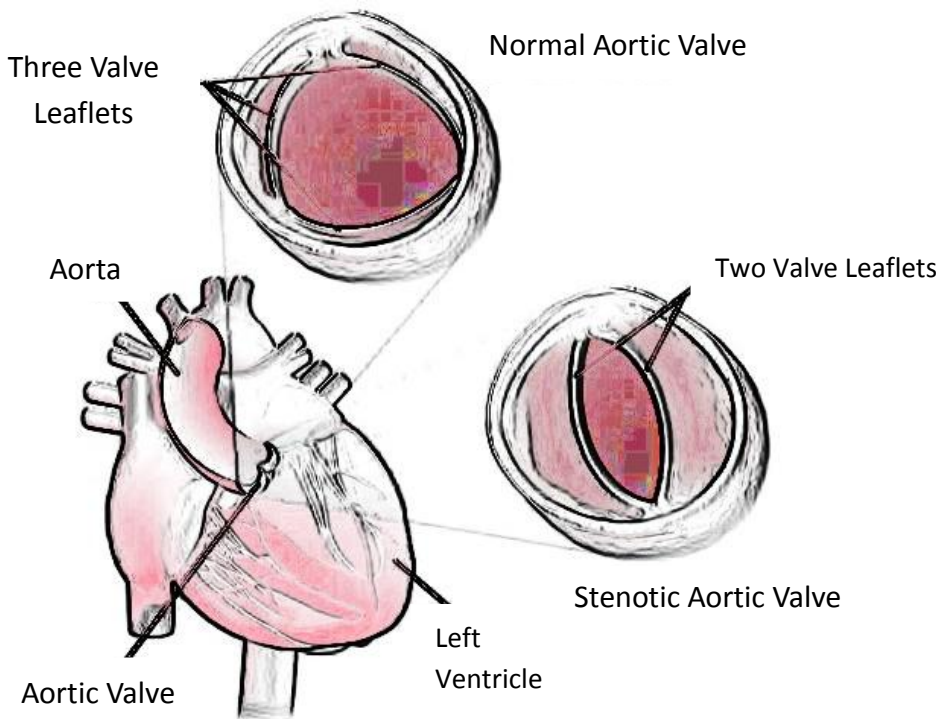


Figure 1.6c Congenital aortic valve stenosis

d. Congenital aortic valve insufficiency

- Description: This is characterized by an incomplete closure of the valve leading to backward flow of blood from the aorta into the left ventricle.

- Symptoms:

Usually asymptomatic at birth. If severe insufficiency symptoms include:

- Lethargy or poor feeding
 - Bounding pulse
 - Dyspnea
 - Tachypnea
 - Irregular pulse /arrhythmia
- Other associated anomalies:
 - Ventricular septal defect
 - Bicuspid aortic valve disease

Failure of the aortic valve to close tightly causes back flow of blood into the left ventricle

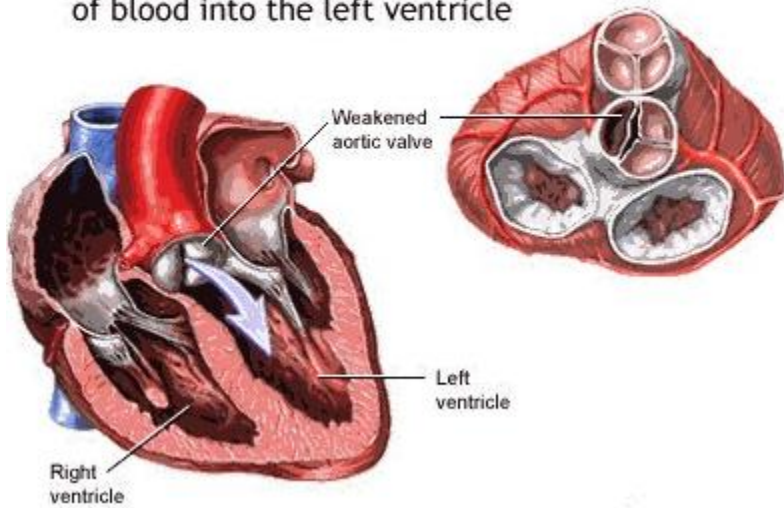


Figure 1.6d Congenital aortic valve insufficiency

I.7. Malformations of the pulmonary & tricuspid valves

- **Description:** This is a group of malformations characterized by a narrowing or insufficiency of the tricuspid or pulmonary valves. This group includes
 - Pulmonary valve stenosis or atresia
 - Pulmonary valve insufficiency
 - Tricuspid atresia
 - Ebstein's Anomaly
 - Hypoplastic right heart syndrome.

a. Pulmonary valve stenosis

- **Description:** Isolated pulmonary valve stenosis with intact ventricular septum is relatively common accounting for 8-10% of all cardiac defects. It causes obstruction to the ejection of blood from the right ventricle leading to an increase in the right ventricular pressure
- **Symptoms:**
 - Most are asymptomatic
 - Depend on the severity of the stenosis
 - Mild to severe dyspnea and fatigue
 - Cyanosis if right to left shunt through PFO or ASD
- **Other associated anomalies:**
 - Obstructive lesions of the right ventricle and pulmonary artery tree
 - Noonan's syndrome.

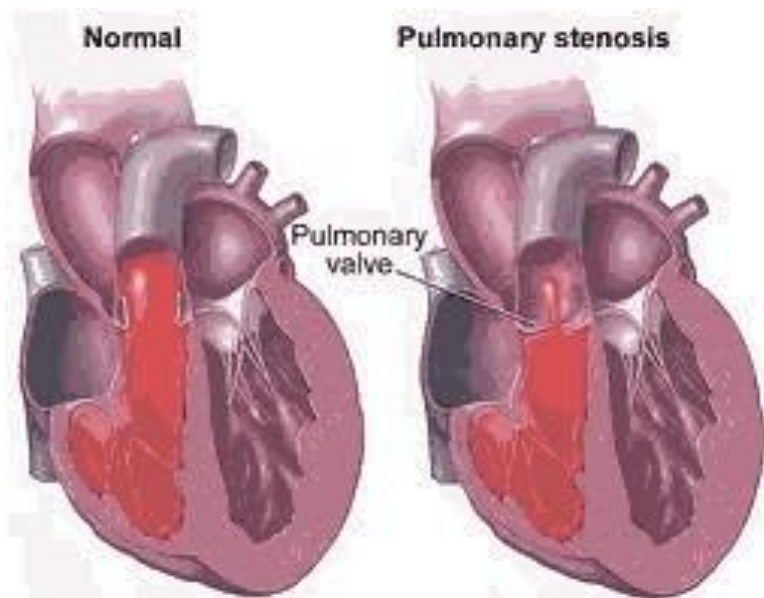


Figure 1.7a Pulmonary valve stenosis

b. Pulmonary valve atresia

- Description: Pulmonary atresia with intact ventricular septum is one of the common congenital cyanotic heart defects. By definition, the pulmonary valve is sealed or imperforated and pulmonary blood flow is provided through the patent ductus arteriosus.

- Symptoms:
 - Cyanosis few hours after birth as the ductus closes
 - Tachypnea with no dyspnea
 - Hypoxemia refractory to Oxygen administration
 - Significant metabolic acidosis reflects tissue hypoxic damage
 - Soft pansystolic murmur at the left lower sternal border

- Other anomalies associations:
 - Septal defects
 - Tricuspid atresia
 - Proximal pulmonary artery atresia
 - Aortic stenosis
 - Ebstein anomaly of tricuspid leaflets

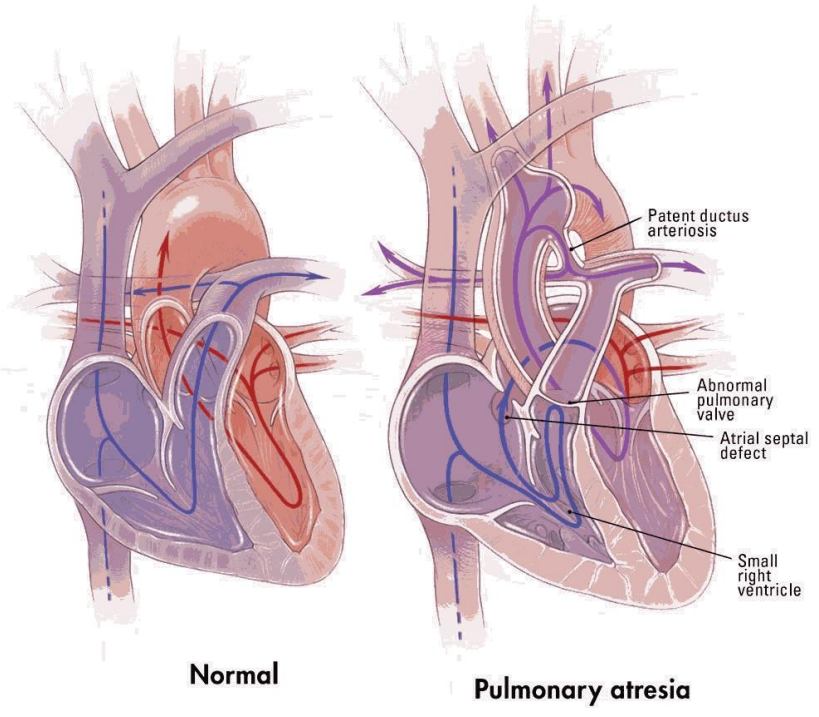


Figure 1.7b Pulmonary valve atresia

c. **Congenital pulmonary valve insufficiency**

- Description: Also known as pulmonary valve regurgitation or pulmonary incompetence. Pulmonary valve flaps do not close tightly allowing blood to flow backward, resulting in a distinct murmur.

- Symptoms:

None or soft heart murmur.

- Other anomalies associations:
 - Fallot's tetralogy
 - Atrial septal defect (ASD)
 - Ventricular septal defect (VSD)
 - Patent Ductus Arteriosus (PDA)
 - Noonan's Syndrome

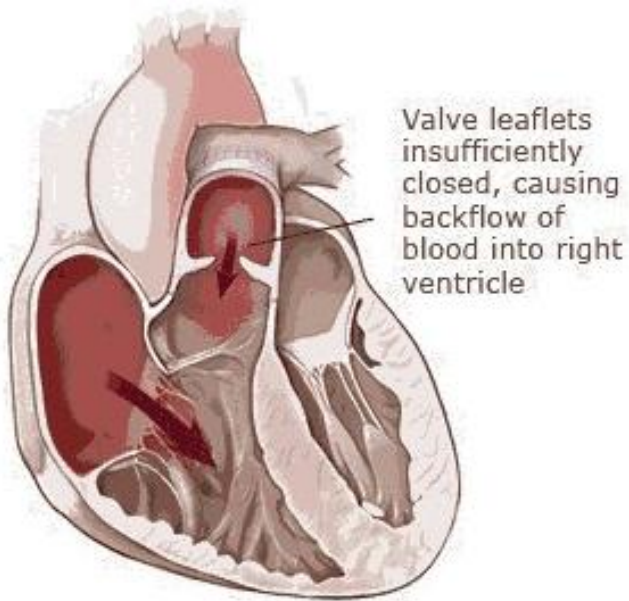


Figure 1.7c Congenital pulmonary valve insufficiency

d. Congenital tricuspid atresia / Hypoplastic Right Heart Syndrome

- Description: Tricuspid atresia is defined as complete agenesis or absence of the tricuspid valve with no communication between the right atrium and the right ventricle. This will result in an underdeveloped right ventricle or hypoplastic right ventricle.

- Symptoms:
 - Depend on the pulmonary blood flow
 - Significant cyanosis in the first day of life if decreased pulmonary blood flow
 - Symptoms of heart failure related to increased pulmonary blood flow
 - Heart murmurs depending on the presence of the associated anomalies.

- Other associated anomalies:
 - Dextro transposition of great arteries (D-TGA)
 - Atrial septal defect (ASD)
 - Ventricular septal defect (VSD)
 - Patent ductus arteriosus (PDA)
 - L- transposition or malposition of the great arteries.

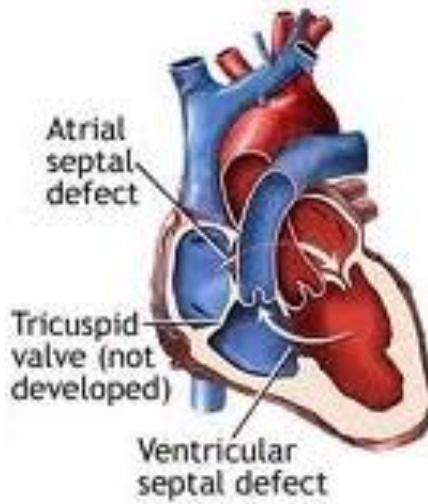


Figure 1.7d(A) Congenital tricuspid atresia

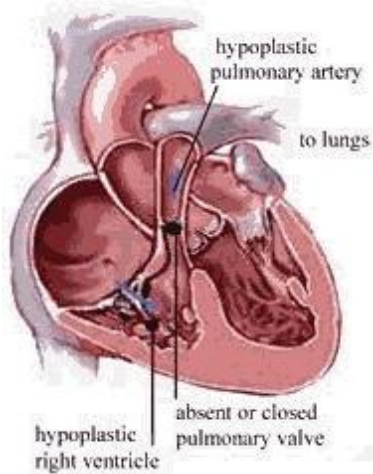


Figure 1.7d(B) Hypoplastic right heart syndrome

e. **Ebstein's Anomaly**

- Description: The tricuspid valve in Ebstein's anomaly is variably displaced downward into the right ventricle and its leaflets are redundant this forms an "atrialized" portion of the right ventricle that is continuous with the right atrium. It occurs in approximately 0.5% of patients with cardiac defects.

- Symptoms:
 - May be asymptomatic at birth if mild deformation
 - May present with severe congestive heart failure and cyanosis in severe cases
 - Holosystolic murmur of tricuspid regurgitation
 - Gallop rhythm in heart failure

- Other associated anomalies:
 - Interatrial communication
 - Ventricular septal defect (VSD)
 - Pulmonary stenosis or atresia

Ebstein's anomaly

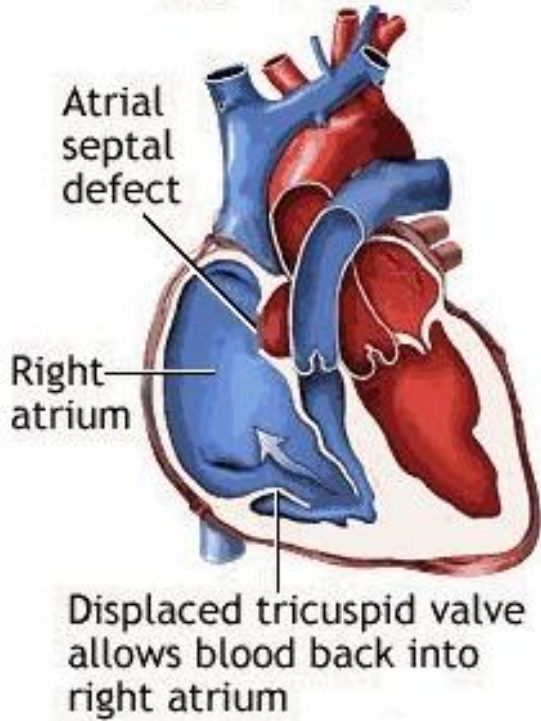


Figure 1.7e Ebstein's anomaly

I.8. Congenital pulmonary valve stenosis

Refer to I.7a for more on description, symptoms, and other anomalies associations.

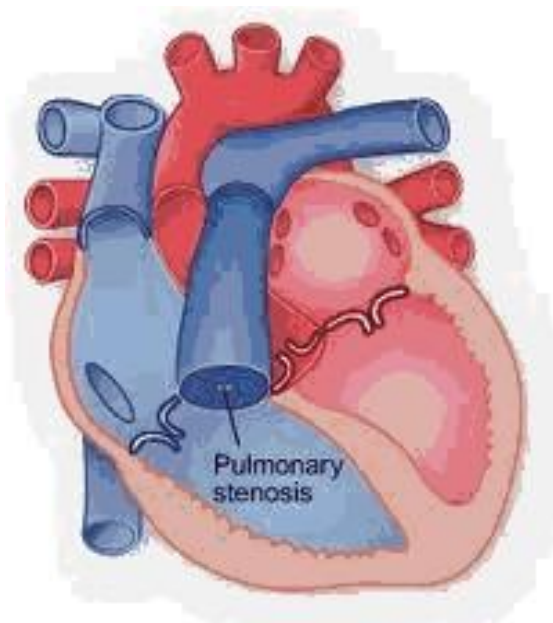
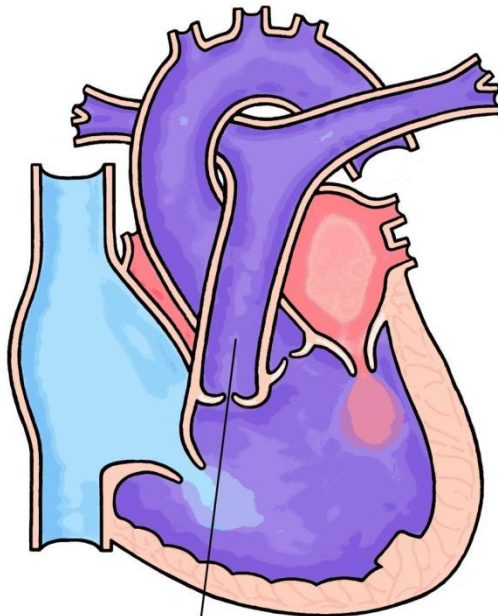


Figure 1.8 Pulmonary valve stenosis

I.9. Single Ventricle

- Description: It is a rare defect, characterized by one ventricle receiving two atrioventricular valves. Often occurs as part of complex cardiovascular abnormalities. Single ventricle physiology comprise a variety of anatomic lesions, usually associated with atresia of AV valve whereby there is complete mixing of systemic and pulmonary venous return. The ventricular output is split between the pulmonary and systemic vascular bed.
- Symptoms:
 - Signs of shock in first week of life (see HLHS)
 - Acidosis
 - Failed hyperoxia challenge: no increase in PaO₂ >150 on 100% oxygen



Physiology depends on the degree of pulmonary stenosis which determines the amount of pulmonary blood flow

Figure 1.9 Single ventricle

I.10. Tetralogy of Fallot (TOF)

- Description: Tetralogy of Fallot is considered the most common cyanotic heart defect. It includes three variations:
 - Classic TOF consists of four defects:
 - Ventricular septal defect (VSD)
 - Pulmonary valve stenosis (PS)
 - Overriding aorta (displacement of the aorta to the right)
 - Right ventricular hypertrophy
 - TOF with pulmonary atresia
 - TOF with absent pulmonary valve
- Symptoms:
 - Severity depends on the degree of pulmonary stenosis
 - Cyanosis may present at birth or appear gradually
 - Dyspnea with feeding
 - Poor growth
 - “TET” spells: sudden, potentially lethal episodes of severe cyanosis due to decreased pulmonary blood flow.
 - Harsh systolic murmur mostly at the left upper sternal border with single S₂.
- Other associated anomalies:
 - Down syndrome
 - DiGeorge syndrome
 - CHARGE syndrome
 - VACTERL syndrome

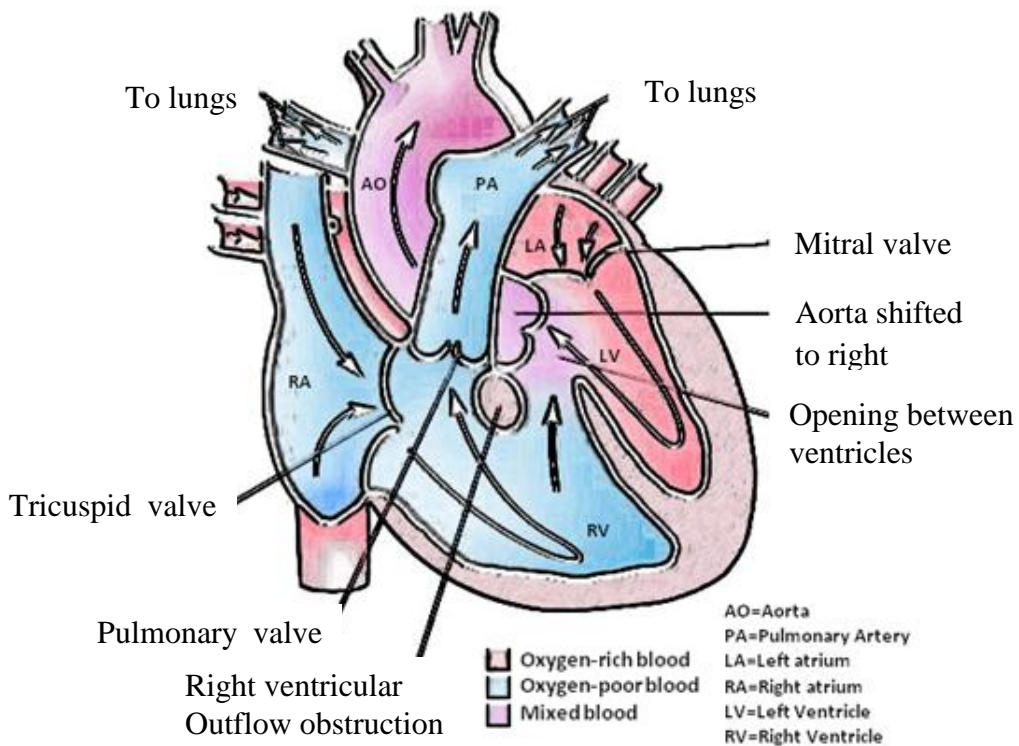


Figure 1.10 Tetralogy of Fallot

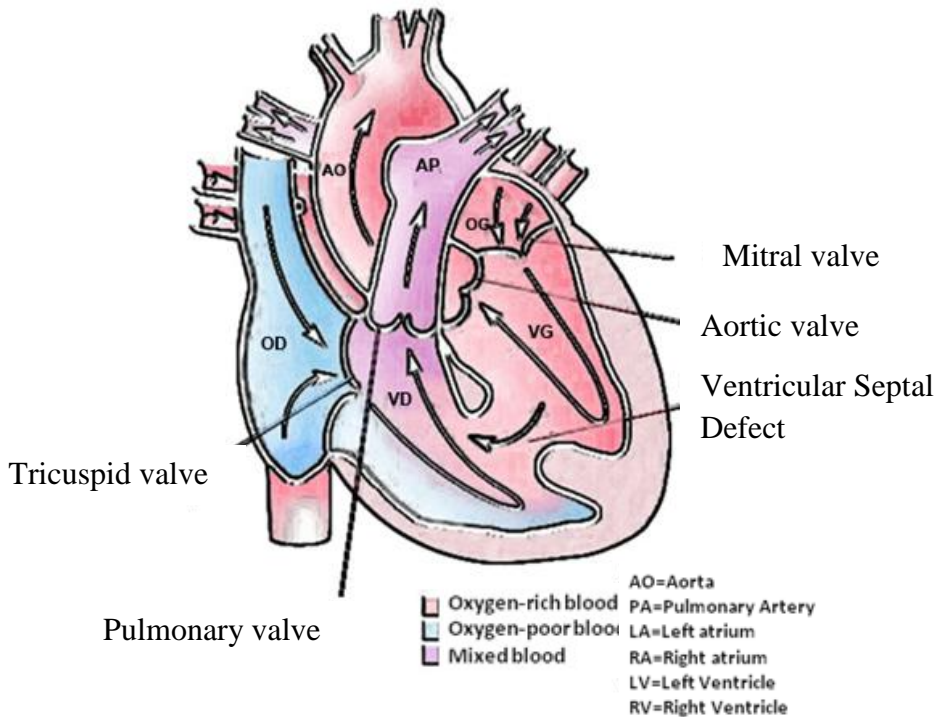
I.11. Ventricular Septal Defect (VSD)

- Description: VSD is the most common cardiac defect accounting for 20% of all congenital heart diseases. It is characterized by one or more openings in the ventricular septum resulting in blood shunt between the ventricles usually left to right. Large defects may lead to congestive heart failure due to excessive shunting.

- Symptoms:

Severity depends on the size of the defect.

- Tachypnea with increased respiratory efforts
 - Excessive sweating
 - Fatigue or dyspnea with feeding and poor growth.
 - On auscultation: loud, harsh, holosystolic murmur at the lower left sternal border, sometimes associated with a thrill
 - Respiratory infections often precede signs of failure
- Other associated anomalies:
 - Many chromosomal anomalies
 - Trisomies 21, 18 and 13



Chapter II: Cleft lip and cleft palate

In this section:

- II. Introduction
- II.1. Cleft lip
- II.2. Cleft palate

II. Introduction:^{1,6}

- Cleft lip and/or palate are orofacial defects that occur during the embryonic period resulting in a partial or complete fissure or opening in the lip alone (called isolated cleft lip) or in the palate alone (called isolated cleft palate) or in both lip and palate.
- If left untreated surgically, these malformations present serious problems related to feeding, respiratory, middle ear infections, speech and socialization.
- Cleft lip and/or palate are usually associated with many syndromes caused by chromosomal abnormalities.
- A simple physical examination at birth can diagnose these malformations.

II.1. Cleft lip

- Description: Cleft lip is the presence of one or two vertical fissures (clefts) in the upper lip and if severe it can extend in the bottom of the nose or the upper gum. Cleft lip can be one sided (unilateral) or two sided (bilateral) resulting from failure of fusion of the maxillary and medial nasal processes (formation of the primary palate). It can occur with or without cleft palate.
- Symptoms:
A cleft lip is noted at birth by the presence of a notch or gap in either one or both sides of the upper lip. It can also extend into the gum line.
- Other possible anomalies associations:
 - Van der Woude syndorme
 - Pierre Robin syndrome

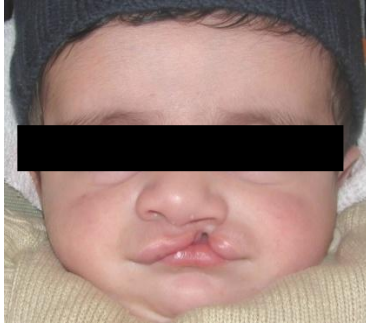

Figure 2.1a⁶ Unilateral cleft lip

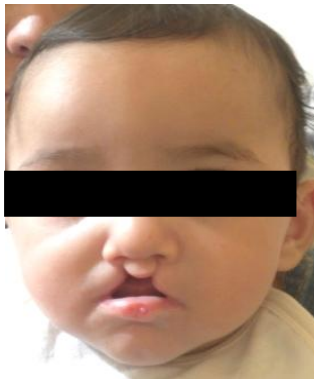

Figure 2.1b⁶ Bilateral cleft lip

II.2. Cleft palate

- Description: Cleft palate is a treatable birth defect in which the baby's roof of the mouth (palate) does not develop normally during pregnancy, leaving an opening (cleft) that may go through to the nasal cavity. Cleft palate may involve any part of the palate, including the front part of the roof of the mouth (hard palate) or the small tag of tissue that hangs down from the soft palate (uvula).

- Symptoms:

No symptoms are shown at birth. However, it can be noticed by feeding problems characterized by the inability to suck and swallow normally.

- Diagnostic tools/test to perform:

- Examination of the oral region at birth (although high resolution ultrasound may reveal the presence of a cleft lip / palate as early as 14 to 16 weeks of gestation)
- Thorough physical examination to rule out any other associated defect or abnormality.
- Cardiac and abdominal Ultra-sound scan to rule out associated abnormalities.
- Chromosome analysis on peripheral blood.
- When available a genetic consultation can determine if the cleft is an isolated condition or part of another syndrome or condition.

- Other possible anomalies associations:

- Congenital heart anomalies
- Renal abnormalities
- Chromosomal abnormalities

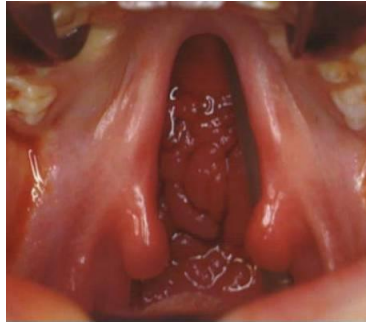


Figure 2.2a⁶ Cleft palate

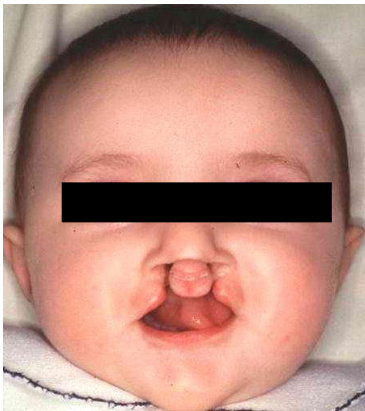

Figure 2.2b⁶ Cleft lip and palate bilateral total

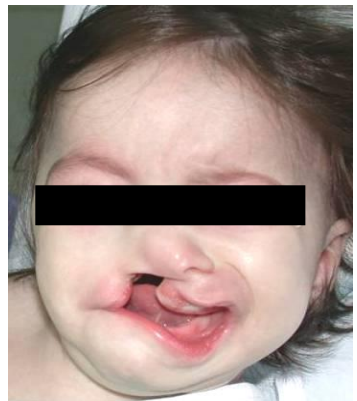

Figure 2.2c⁶ Unilateral cleft lip and palate

Chapter III: Chromosomal Abnormalities

In this section:

- III. Introduction
- III.1. Down's Syndrome (T21)
- III.2. Edward's Syndrome, unspecified (T18)
- III.3. Patau's syndrome, unspecified (T13)

III. Introduction: ^{2, 7-12}

- Chromosomal abnormalities occur from errors in the number or structure (i.e. rearrangements) of chromosomes mostly during the formation of an egg or sperm.
- These errors can lead to various types of birth defects affecting generally multiple organ systems which make them easy to detect.
- Many chromosomal abnormalities such as triploidy (three sets of 23 chromosomes) are aborted in the first trimester of pregnancy.
- About 1 in 150 babies is born with a chromosomal abnormality.
- Infants born with these malformations suffer from mental retardation and/ or physical burden.
- Most common chromosomal abnormalities include trisomy 21, 18 and 13.
- Advanced maternal age increases the risk of chromosomal abnormalities.

III.1. Down's Syndrome (T21)

- Description: Down syndrome is a chromosomal abnormality characterized by a third extra copy of chromosome 21 (instead of two). The extra copy can be free-lying, or can be attached to some other chromosome, most frequently number 14. This syndrome occurs in 1/660 newborns. Trisomy 21 is associated with an advanced maternal age (≥ 35 years) age.
- Symptoms may include:
 - Hypotonic infants
 - Flat facial profile (particularly flattening of the bridge of the nose)
 - Widely spaced and up-slanted eyes
 - A flattened occiput, microcephaly, and extra skin around the back of the neck
 - Brushfield's spots (gray to white spots resembling grains of salt around the periphery of the iris) may be visible.
 - The mouth is often held open because of a large, protruding, furrowed tongue that lacks the central fissure.
 - Small rounded ears
 - Short hands and fingers
 - Wide gap between the 1st and 2nd toes
- Diagnostic tools/test to perform:
 - Chromosome analysis on peripheral blood (in case prenatal diagnosis was not done)
 - Cardiac and Abdominal Ultrasound scan
- Other anomalies associations:
Cardiac anomalies (Endocardial cushion defect, VSD, PDA, ASD, TOF)

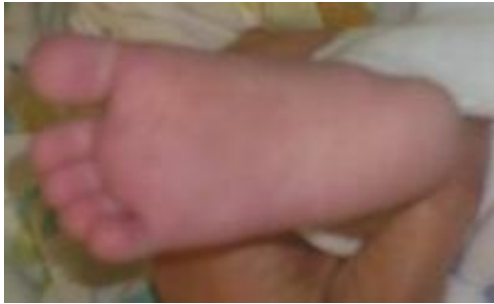

Figure 3.1a¹¹ Down's Syndrome (T21),
(wide gap between the 1st and 2nd toes)

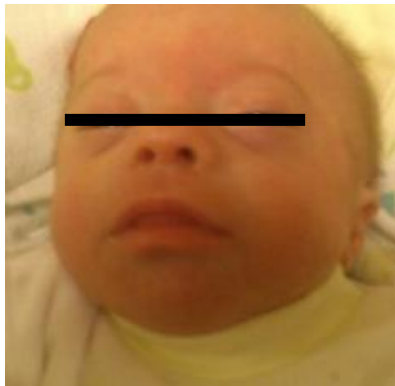

Figure 3.1b¹¹ Down's Syndrome (T21),
(widely spaced and up-slanted eyes,
protruding tongue)

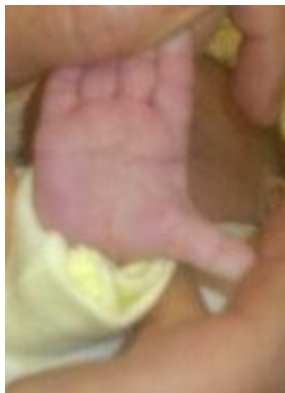

Figure 3.1c¹¹ Down's Syndrome (T21),
(simple crease)

III.2. Edward's Syndrome, unspecified (T18)

- Description: Trisomy 18, also called Edwards syndrome, is a chromosomal condition characterized by an extra copy of chromosome 18 which can be free lying or attached to another chromosome. The prevalence is approximately 1 in 6,000. It is associated with high mortality rate in utero and in the neonatal period.

- Symptoms:
 - Severe psychomotor and growth retardation
 - Microphthalmia (small eyes)
 - Low birth weight
 - Low set ears
 - skull malformation and short digits
 - A small jaw and mouth (Micrognathia)
 - Clenched fists with overlapping fingers, clinodactyly (incurving of fifth finger)
 - Deformed feet known as "rocker-bottom feet"
 - Syndactyly
 - Limited hip abduction

- Diagnostic tools/test to perform:
 - Chromosome analysis on peripheral blood. (in case prenatal diagnosis was not done)
 - Cardiac and Abdominal Ultrasound scan
 - Computed tomography (CT) / magnetic resonance imaging (MRI) of the brain

- Other anomalies associations:
 - Heart defects
 - Renal defect
 - Central nervous system anomalies

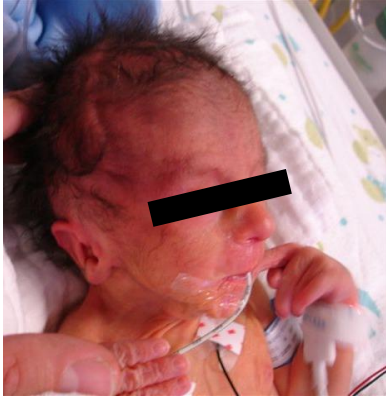

Figure 3.2a¹¹ Edward's syndrome (T18),
(low set ears)

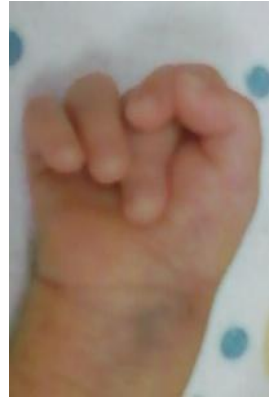

Figure 3.2b¹¹ Clinodactyly with
clenched fists with overlapping
fingers in T18

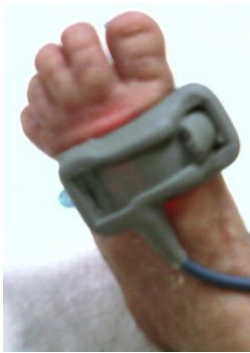

Figure 3.2c¹¹ Syndactyly in T18

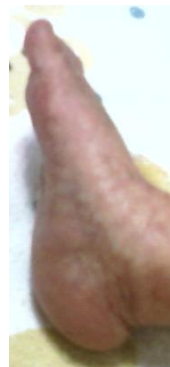

Figure 3.2d¹¹ Rocker-bottom
foot in T18

III.3. Patau's syndrome, unspecified (T13)

- Description: Patau syndrome (or trisomy 13) is a congenital disorder associated with the presence of an extra copy of chromosome 13. The prevalence is approximately 1 in 10,000. It is associated with high mortality rate in utero and in the neonatal period
- Symptoms:
 - Mental & motor deficit
 - Polydactyly (extra digits)
 - Microcephaly (abnormally small head)
 - Structural eye defects
 - Cleft palate
 - Meningomyelocele (a spinal defect)
 - Omphalocele (abdominal defect)
 - Abnormal genitalia
 - Cutis aplasia (missing portion of the skin/hair)
 - Prominent heel
 - Rocker-bottom feet
 - The presence of other congenital malformations
- Diagnostic tools/test to perform:
 - Chromosome analysis on peripheral blood. (in case prenatal diagnosis was not done)
 - Cardiac and Abdominal Ultrasound scan
 - MRI/ CT scan of the brain
- Other anomalies associations:
 - Heart defects
 - Renal defects
 - Central nervous system anomalies

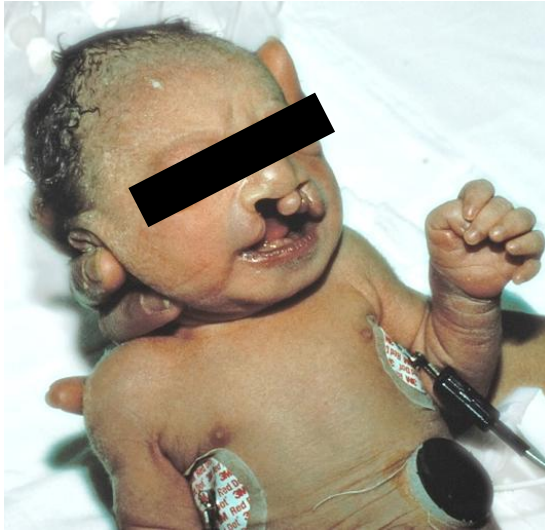

Figure 3.3¹² Trisomy 13 with Cleft lip/palate

Chapter IV: Congenital malformations and deformations of the musculoskeletal system

In this section:

- IV. Introduction
- IV.1. Congenital dislocation of hip, unspecified
- IV.2. Diaphragmatic Hernia
- IV.3. Gastroschisis
- IV.4. Omphalocele
- IV.5. Polydactyly
- IV.6. Syndactyly
- IV.7. Club Foot
- IV.8. Reduction defects of the limb(s)

IV. **Introduction:** ^{11, 13-40}

- Congenital Musculoskeletal abnormalities include defects of the extremities, spine and pelvis in addition to muscular defects such as diaphragmatic hernia and abdominal wall defects (Gastroschisis, omphalocele, prune belly among others).
- Most of the musculoskeletal defects are apparent at birth with the exception of developmental hip dysplasia.
- Bony deformities should prompt the physician to screen for other associated major malformations especially neuromuscular diseases.
- In addition, a karyotype is warranted in case of abdominal wall defects more specifically omphalocele.

IV.1. Congenital dislocation of hip, unspecified

- Description: A condition of abnormal development of the hip, present either at birth or shortly after, resulting in hip joint instability and potential dislocation of the thigh bone from the socket in the pelvis. Approximately one in 1,000 children is born with a dislocated hip⁴¹.
- Symptoms: Symptoms can include:
 - Different (asymmetric) leg positions
 - Reduced movement on the side of the body affected by the disorder
 - Shorter leg on the affected side
 - Uneven folds of thigh fat
- Diagnostic tools/test to perform:
 - Physical Exam that can be done in three methods:
 - Ortolani method (Fig. 4.1b):
 - Performed in the first three months.
 - Place one's index and long fingers laterally over the child's greater trochanter with the thumb medially along the inner thigh near the groin crease.
 - A gentle upward force is applied while the hip is abducted (legs moved apart).
 - A palpable "clunk" is a positive Ortolani test and represents the reduction of a dislocated hip into the bony acetabulum.
 - Barlow method:
 - Performed the first three months.
 - Same technique as Ortolani but a gentle downward force is applied instead while the hip is adducted.
 - Galeazzi method:
 - Also called Allis sign

- Is performed by placing the child supine with both hips and knees flexed
- An inequality in the height of the knees is a positive Galeazzi sign
- Ultrasound of the hip performed at four months or younger.
- X-ray of the hip joint performed beyond four months.

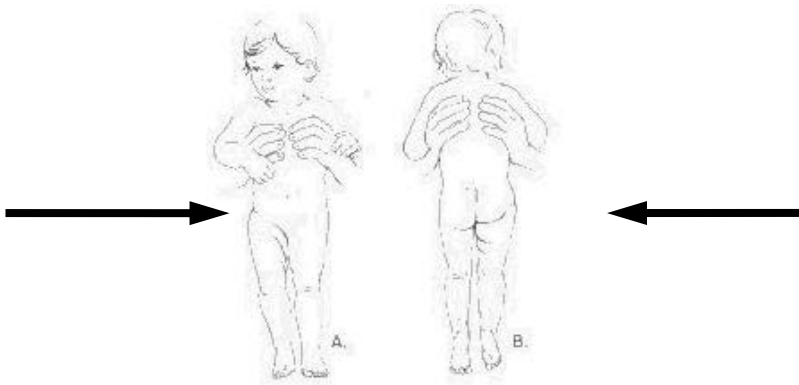


Figure 4.1a Congenital dislocation of the hip

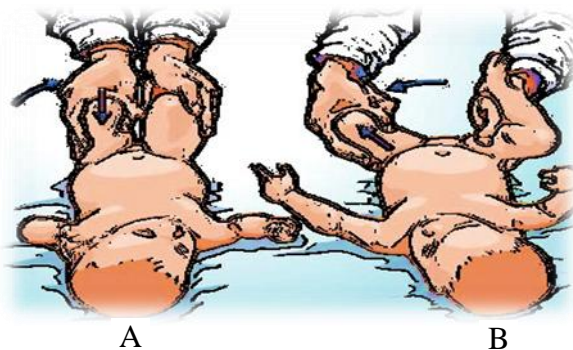


Figure 4.1b¹³ Barlow Maneuver (A) and Ortolani Maneuver (B)

IV.2.Diaphragmatic Hernia

- **Description:** A birth defect where the diaphragmatic muscle is abnormally opened to allow parts of the abdominal organs (such as the stomach, small intestine, spleen, part of the liver, and the kidney) to move into the chest area. The defect is more common on the left, but can also occur on the right. Congenital diaphragmatic hernia (DH) is seen in 1 out of 2,200 to 5, 000 live births.
- **Symptoms:**
 - Depend on the magnitude of the defect
 - Severe breathing difficulty developed usually after the baby is born
 - Bluish colored skin due to lack of oxygen (cyanosis)
 - Rapid breathing (tachypnea)
 - Fast heart rate (tachycardia)
- **Diagnosis:**
 - Physical examination that may show irregular chest movements, absent breath sounds on affected side, bowel sounds in the chest, and the abdomen feels less full on examination by touch (palpation).
 - Fetal ultrasound that may show abdominal contents in the chest cavity.
 - Chest x-ray that may show abdominal organs in chest cavity
- **Associated Anomalies:**

As many as 50 percent of infants with DH will have an associated anomaly of the following:

 - Central nervous system (neural tube defects)
 - Cardiovascular (mostly ventricular septal defect, univentricular anatomy (heart hypoplasia), aortic arch obstruction, and tetralogy of fallot)
 - Skeletal
 - Gastrointestinal
 - Genitourinary
 - Chromosomal anomalies

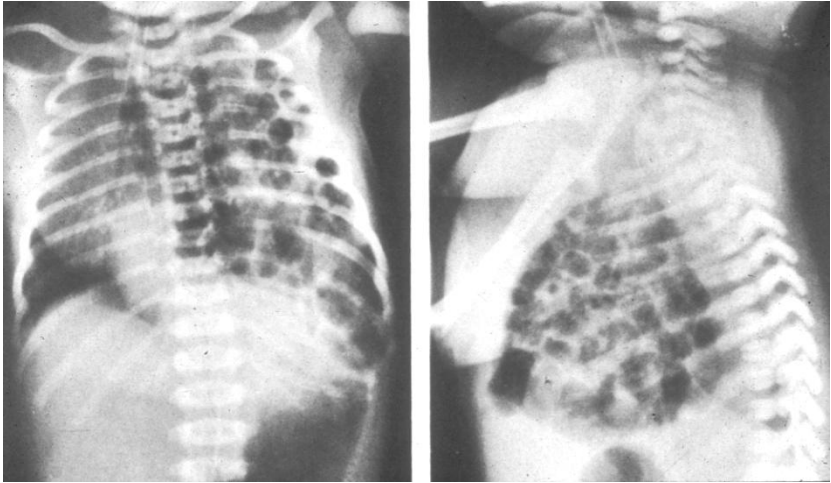


Figure 4.2⁴⁰ Diaphragmatic hernia (Chest X-ray)

IV.3.Gastroschisis

- Description: A birth defect in which a portion of an infant's intestines protrude out of the abdomen through a small hole in the body wall beside the umbilical cord due to the inability of the abdominal wall to close completely (Fig.4.3). The defect can be small or large with other organs such as the liver involved. Gastroschisis is a type of hernia and is also called paraomphalocele, laparoschisis, or abdominoschisis. Prevalence is estimated to be 1 out of every 2,500 babies each year.
- Symptoms:
 - Lump in the abdomen
 - Intestine sticks through the abdominal wall near the umbilical cord
 - Problems with movement and absorption in the gut due to the unprotected intestine being exposed to irritating amniotic fluid
- Diagnosis:
 - Physical examination of the infant
 - Prenatal Ultrasound detects signs in the pregnant mother such as polyhydramnios (excessive amniotic fluid)
- Associated Anomalies: Other gastrointestinal anomalies such as intestinal atresia, stenosis, and malrotation.

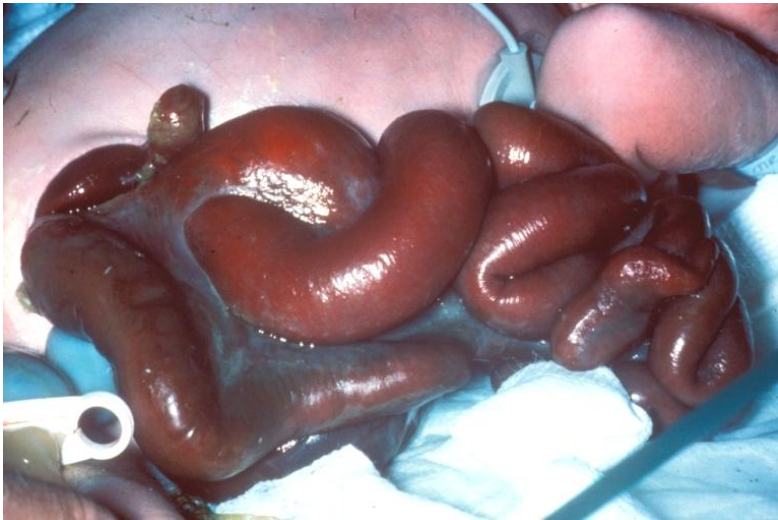

Figure 4.3⁴⁰ Gastroschisis

IV.4. Omphalocele

- Description: Specific type of abdominal wall defect in which some of the infant's internal organs protrude through the abdominal muscles in the area around the umbilical cord. Omphalocele may be minor, involving only a small portion of the intestines, or it may be severe with most of the abdominal organs, such as the intestines, liver, and spleen, outside the body. It is a type of hernia with an incidence of 1 out of 5,000 births. Usually occurs in full-term infants, more common in males than in females.

- Symptoms:

At birth, an omphalocele can be clearly seen, because the abdominal contents stick out (protrude) through the belly button area (Fig.4.4)

- Diagnosis:

- Diagnosis is possible by prenatal ultrasound
- Otherwise, physical examination of the newborn is sufficient to make the diagnosis.
- Amniocentesis or other means of fetal karyo-typing are often recommended to rule out associated chromosomal abnormalities.
- X-rays are usually taken of the heart, lungs, and diaphragm once the infant's condition has been stabilized after birth to check for other associated congenital defects.

- Associated Anomalies:

- Approximately 50 - 75 % of infants with an omphalocele have associated congenital anomalies
- 20 -35% have chromosomal abnormalities, most commonly trisomy 13 and 18.
- 25 - 40% have other birth defects such as heart defects (tetralogy of Fallot), imperforated anus, neural tube defects, diaphragmatic hernia, anomalies of the urinary and skeletal systems, Beckwith-Wiedemann syndrome, with enlarged tongue, gigantism, and enlarged internal organs, pentalogy of Cantrell, with malformations in the chest and abdominal area.

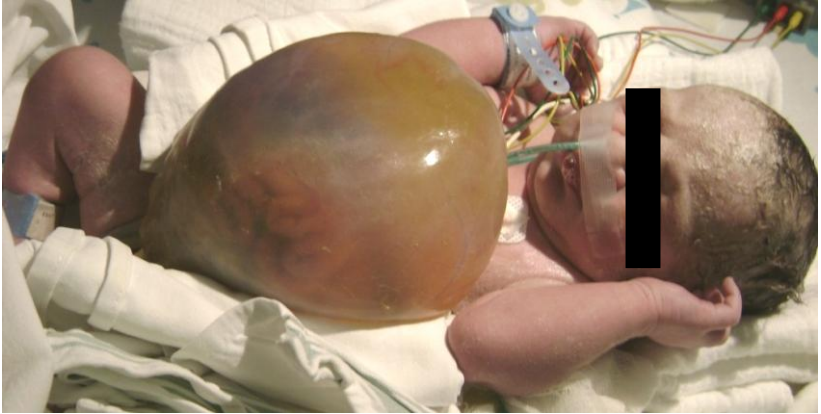

Figure 4.4a¹¹ Omphalocele

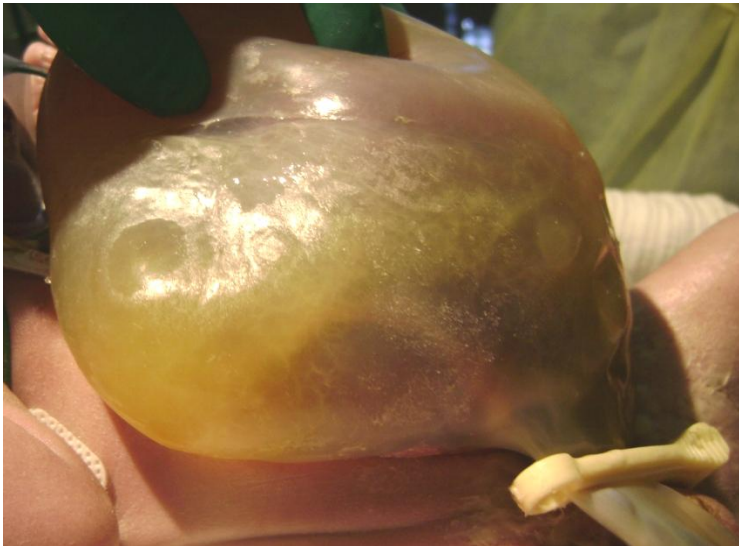

Figure 4.4b¹¹ Omphalocele

IV.5. Polydactyly

- Description:
 - Minor condition characterized by an extra digit: an accessory finger, thumb or toe (including accessory hallux).
 - Occur with a triphalangeal thumb malformation.
- Diagnosis:
 - Fetal ultrasound
 - Physical exam at birth
 - X- rays
- Associated anomalies:

Polydactyly is most of the time an isolated familial defect; however it can be associated with many syndromes including:

- Acrocallosal syndrome
- Basal cell nevus syndrome
- Bardet-Biedl syndrome
- Biemond syndrome
- Ectrodactyly-ectodermal dysplasias-cleft lip/palate syndrome
- Ellis van Creveld syndrome
- Meckel Gruber syndrome
- McKusick-Kaufman syndrome
- Mirror hand deformity
- Mohr syndrome
- Oral-facial-digital syndrome
- Pallister-Hall syndrome
- Rubinstein-Taybi syndrome
- Short rib polydactyly
- VATER association.

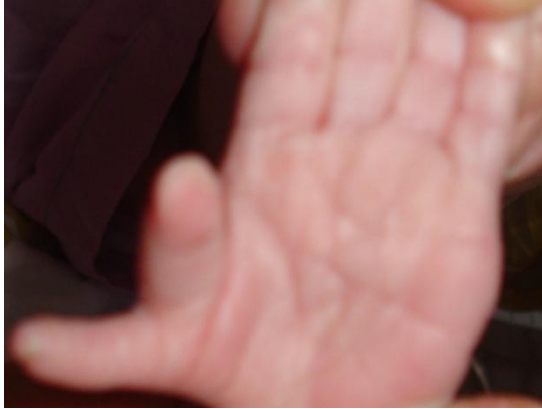

Figure 4.5¹¹ Polydactyly

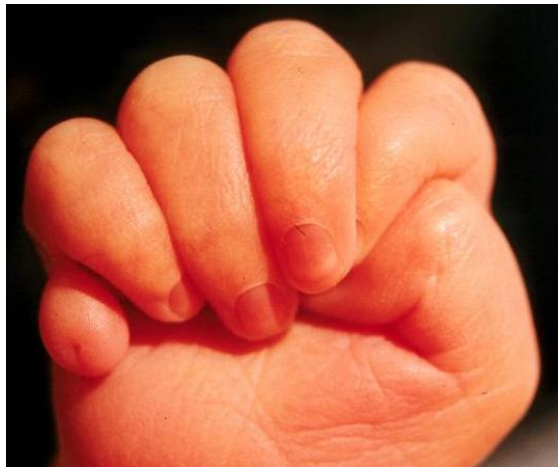

Figure 4.5¹¹ Polydactyly

IV.6.Syndactyly

- Description:
 - Fingers fail to separate into individual appendages.
 - Characterized by webbed or conjoined fingers or toes.
 - Classified as simple when it involves soft tissues only and as complex when it involves the bone or nail of adjacent fingers.
 - Fusion can be complete (with synostosis) or incomplete (without synostosis).
 - Classifications include:
 - Webbed fingers: Simple syndactyly of fingers without synostosis
 - Fused fingers: Complex syndactyly of fingers with synostosis
 - Fused toes: Complex syndactyly of toes with synostosis
 - Polysyndactyly: fusion of more than two fingers or toes
 - Syndactyly, unspecified: including Symphalangy.
- Diagnosis:
 - Physical exam at birth
 - X-rays often used to confirm the diagnosis and identify any underlying involvement of the bones of the fingers and hand.
- Associated syndromes:

Syndactyly is a shared feature of more than 28 syndromes, particularly:

- Craniofacial syndromes, including
 - Apert
 - Holt-Oram syndromes.
- Poland syndrome, in which the chest muscle abnormality is found in association with symbrachydactyly and/or other anomalies of the ipsilateral upper extremity.

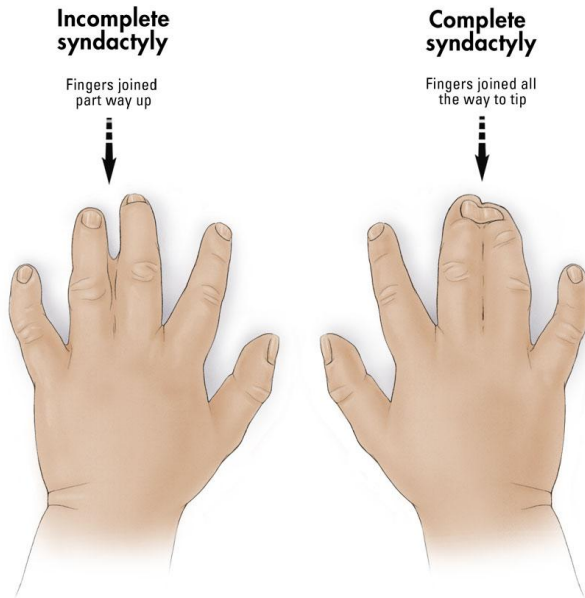


Figure 4.6³⁸ Syndactyly

IV.7.Club foot

- Description: Clubfoot or talipes is a birth defect characterized by an abnormal bone formation in the foot whereby it is twisted (inverted) into an abnormal position at birth. It is common occurring in about one in every 1,000 live births in the United States. It can affect one or both feet, with approximately 50% of the cases being bilateral (Fig.4.7a). Without treatment, persons afflicted often appear to walk on their ankles, or on the sides of their feet.

- Symptoms:

Four different variations are varus, valgus, equines, and calcaneus (Fig.4.7b).

- Varus: Most common characterized by the inward turning and downward pointing of the foot so that the leg and foot look somewhat like the letter J resisting realignment.
- Valgus: When the foot rotates outward to appear like the letter L,
- Equinus: the foot points downward.
- Calcaneus: points upward, with the heel pointing down. The calf muscle of a clubfoot may be smaller and less well developed than normal.

- Diagnosis:

- Physical examination.
- Foot x-ray.

- Other associated anomalies:

- Trisomy 18
- Ehler Danlos syndrome
- Loeys-Dietz

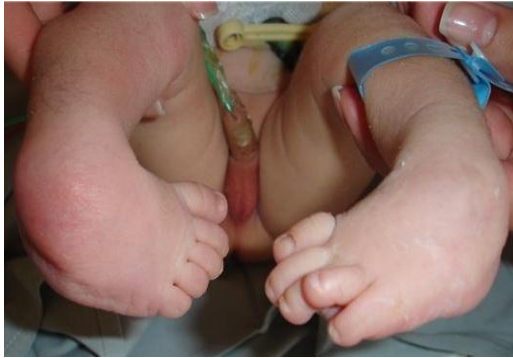

Figure 4.7a¹¹ Clubfoot affecting both feet

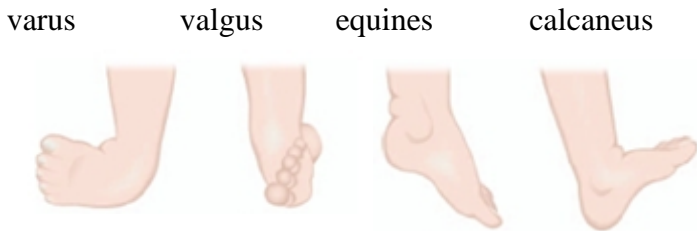


Figure 4.7b¹⁵ Types of clubfoot

IV.8.Reduction defects of the limb(s)

- Description:

Includes all defects affecting upper limbs (absence of upper arm and/or forearm, absence of hand and/or fingers, etc) or lower limbs (absence of thigh and/or lower leg, absence of lower leg and/or foot etc) or reduction defects of unspecified limb.

- Occurs when a part of, or the entire limb of a fetus fails to form completely during pregnancy.
- The naming relates to a limb that is either reduced from its normal size or completely missing affecting its skeletal structure.

- Symptoms:

Difficulties with normal development and motor skills

- Diagnosis:

- Ultrasound: at 18 to 20 weeks
- Femur length is assessed for gestational age in addition to hands and feet.

- Associated anomalies:

- Limb reduction defects (especially those involving the radius or thumb) have been associated with chromosomal anomalies.
- For example, when limb reduction defects are present, the chance of having Trisomy 18 is 1 in 17.

Chapter V: Congenital malformations of the digestive system

In this section:

- V. Introduction
- V.1. Atresia of esophagus without fistula
- V.2. Atresia of esophagus with tracheoesophageal fistula
- V.3. Congenital absence, atresia and stenosis of large intestine: Imperforate anus, stenosis of anus or rectum
- V.4. Congenital absence, atresia and stenosis of small intestine: Intestinal Obstruction
- V.5. Congenital Fistula of rectum and anus
- V.6. Congenital malformations of intestinal fixation
- V.7. Hirschprung's Disease
- V.8. Congenital tracheoesophageal fistula

V. Introduction⁴⁰⁻⁴³

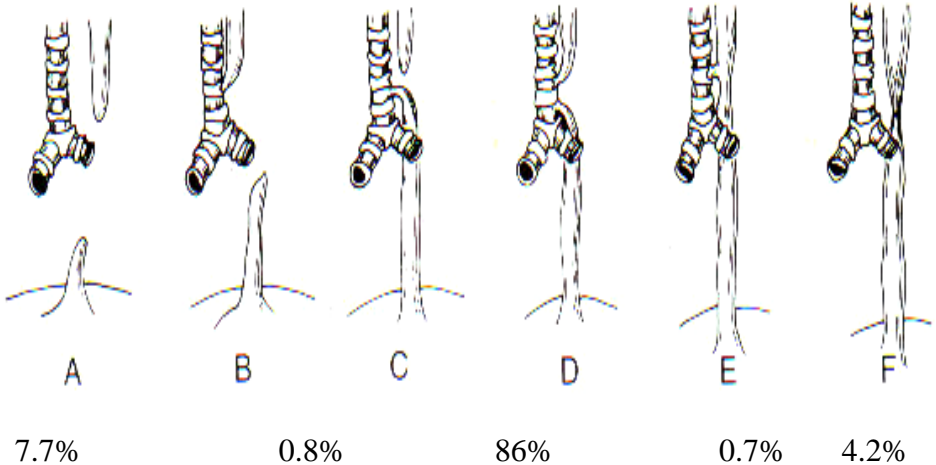
- Congenital anomalies of the gastrointestinal (GI) tract are a significant cause of mortality ranging from 10 to 40%.
- These abnormalities include:
 - Developmental obstructive defects of the small intestine, anomalies of the colon
 - Anomalies of intestinal rotation and fixation
 - Developmental anomalies of the anorectal area and
 - Intestinal duplications.
- About one third of infants with a GI malformation have another congenital anomaly; therefore, malformations of other organ systems, especially of the CNS, heart, and kidneys must be evaluated.
- Symptoms:
 - Vomiting
 - Abdominal distention
 - Obstipation or absence of passage of meconium.
 - In cases of lower intestinal obstruction (distal to the duodenum) the vomiting becomes bilious and the distension is more severe.
 - In cases of malrotation and volvulus, the infant might present with all of the above in addition will appear very sick and may have a surgical abdomen with severe distension, skin discoloration and bloody stools.
- Diagnostic tools/test to perform:
 - Plain Xray (KUB) may suffice in case of complete high intestinal obstruction
 - Contrast enema (preferably gastrografin) in cases suspected to have low obstruction
 - Upper gastrointestinal series: for all patients suspected to have incomplete intestinal obstruction.

- Abdominal ultrasonography (US) done by trained radiologist may help differentiate small bowel obstruction and colonic obstruction.
- Computed tomography (CT) and magnetic resonance imaging (MRI) may provide more anatomic detail and added diagnostic specificity in cases suspected to have malrotation and anorectal anomalies.

V.1. Atresia of esophagus without fistula

- Description: Esophageal atresia is a birth defect in which the esophagus, which connects the mouth to the stomach, is shortened and closed off (dead ended) at some point along its length. This defect almost always occurs in conjunction with tracheoesophageal fistula (TEF), a condition in which the esophagus is improperly attached to the trachea, the "windpipe" that carries air into the lungs.

There are 4 types of TEF depicted in the illustration below with type C or III being the most common.



- When the type is A or F, the birth defect is coded as: ‘Atresia of esophagus without fistula’
- When the type is B, C, D or E, the birth defect is coded: ‘Atresia of esophagus with – tracheoesophageal fistula’
- When type is unknown, the birth defect is coded as nonspecific: ‘Congenital tracheoesophageal fistula NOS’

- Symptoms:
 - Choking / coughing after feeding
 - Excessive salivation
 - Vomiting after each feed as soon as feeding are introduced

- Other anomalies associations:
 - VACTERL Association:
 - Vertebral defects
 - Anorectal malformations
 - Cardiovascular defects
 - Tracheoesophageal defects
 - Ear deformities
 - Renal anomalies
 - Limb deformities
 - Coloboma (eye abnormality)
 - Choanal atresia
 - Developmental retardation
 - Genital hypoplasia

V.2. Atresia of esophagus with tracheoesophageal fistula

Refer to **V.1.** for more on description, symptoms, and other anomalies associations.

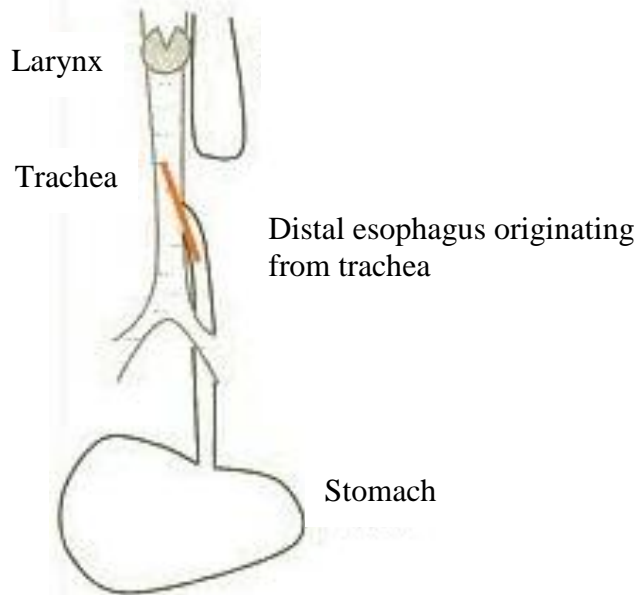


Figure 5.2 Atresia of esophagus with tracheoesophageal fistula

V.3. Congenital absence, atresia and stenosis of large intestine:

Imperforate anus, stenosis of anus or rectum

- Description:

These malformations of the anorectal region include:

- Absence of an anal opening or
- Narrow (stenotic) rectal opening or
- Presence of a rectal fistula, i.e. a communication between the rectum and the urethra, bladder or vagina

- Symptoms:

- Absence of an anal opening on visual exam or
- Presence of a thin translucent membrane covering the anus.
- No passage of stool in the first 24 hours
- Passage of meconium from the vagina or urinary meatus indicates the presence of a fistula

- Other anomalies associations: VACTERL association

Discontinuation
of the colon

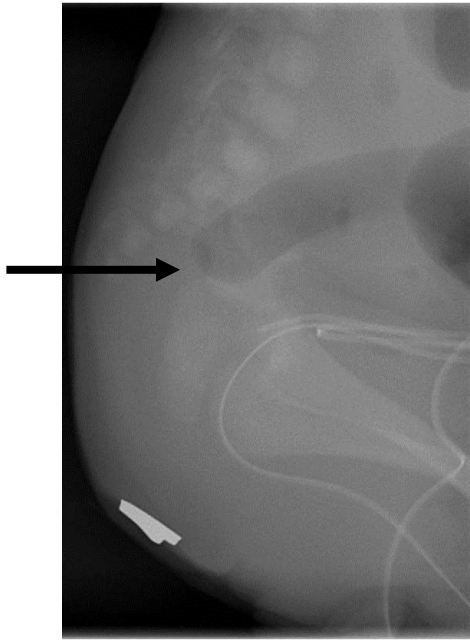


Figure 5.3a¹¹ Imperforate anus

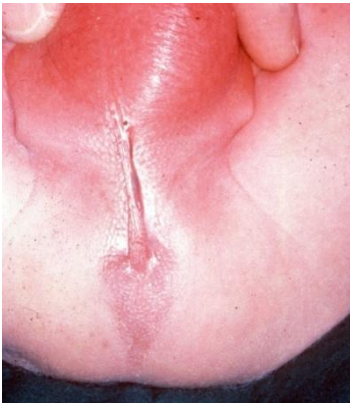

Figure 5.3b⁴⁰ Imperforate anus

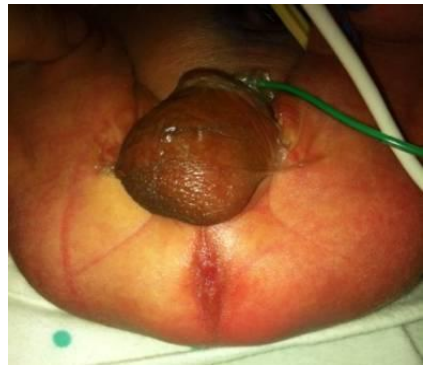

Figure 5.3c¹¹ Imperforate anus

V.4. Congenital absence, atresia and stenosis of small intestine: Intestinal Obstruction

- Description: This group of malformation includes conditions where there is atresia or stenosis of the small bowel (including malformation of the Duodenum, Jejunum and Ileum) and large intestine.

- Symptoms:

They depend on the localization of the obstruction but typically they include:

- Vomiting, bilious or nonbilious
 - Abdominal distension
 - No passage of meconium in the first 24 hours after birth.
- Other anomalies associations:
 - Hirschsprung disease
 - Cardiac, genitourinary, or anorectal defects, and annular pancreas

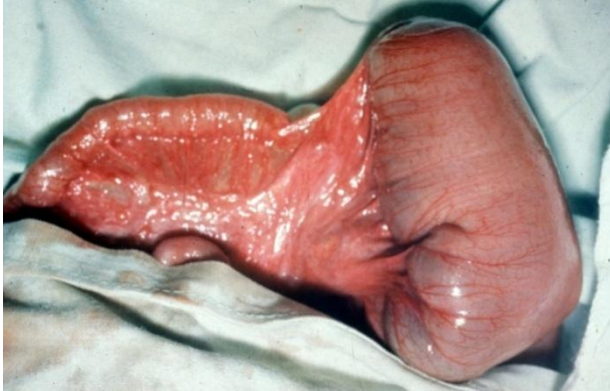

Figure 5.4a⁴⁰ Ileal atresia

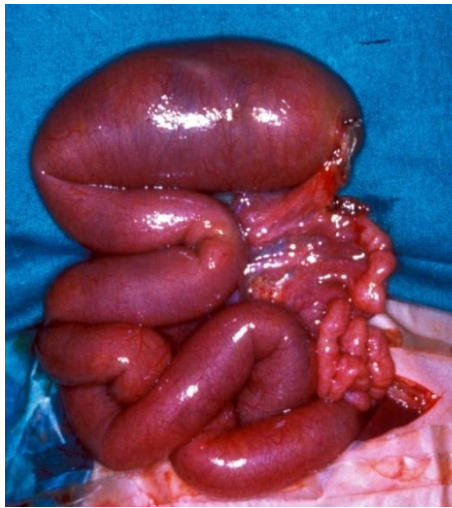


Figure 5.4b⁴⁰ Ileal atresia

V.5. Congenital Fistula of rectum and anus

- Description: This malformation includes the presence of a fistula in both the rectum and the anus. Anatomically, there is an abnormal channel from the anus or rectum to the skin near the anal opening. Occasionally this opening is to another organ such as the vagina, then it is a fistula. Most fistulas begin from a deep gland in the wall of the anus or rectum. However, fistulas may sometimes result from drainage of an ano-rectal abscess.
- Symptoms:
 - Feces coming out from the skin opening
 - Sometimes, pus discharge
- Diagnostic tools/test to perform: Diagnosis is made by visual exam
 - Examination may reveal one or more openings around the anus and the doctor may be able to palpate a cord-like tract.
 - A probe may be inserted to determine the depth and the direction of the fistula.
 - Anoscopy (examination of the anus with an instrument) with probing may help reveal the primary opening.
 - Sigmoidoscopy is also required to rule out concurrent bowel disorder.

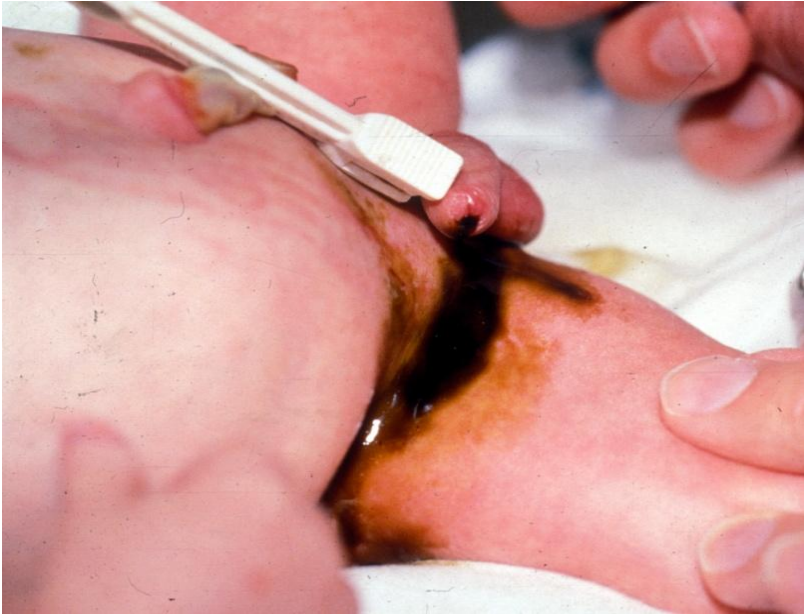

Figure 5.5⁴⁰ Recto urethral fistula

V.6. Congenital malformations of intestinal fixation

- Description: This is a congenital condition whereby the intestines do not undergo the normal rotation and fixation that usually occur during fetal development. This may lead in some cases to intestinal obstruction and mesenteric vessels compromise (volvulus) resulting in intestinal necrosis.

- Symptoms:
 - Irritability
 - Lethargic
 - Signs of abdominal cramping :
 - Pulling legs up and crying then sudden stop
 - Similar repetitive behavior alternating with normal behavior
 - Diarrhea and/or bloody stools, or absence of stools in complete obstruction

- Other associated anomalies: Malrotation of the colon

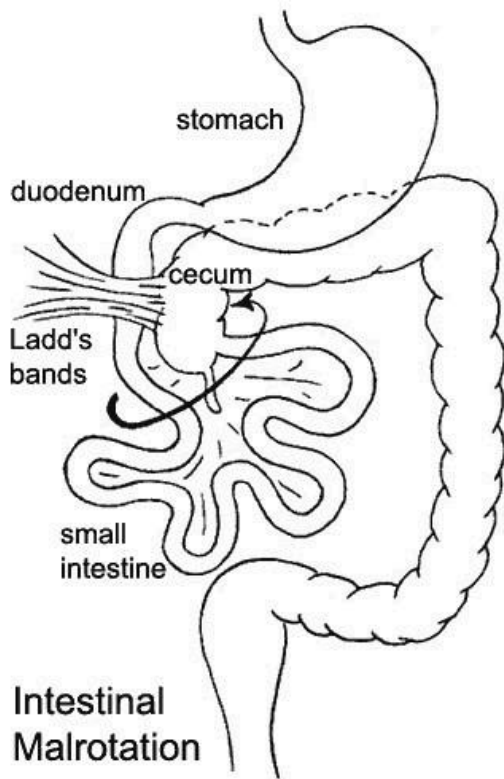


Figure 5.6 Congenital malformation of intestinal fixation

V.7. Hirschprung's Disease

- Description: This is a condition where the colon is enlarged and causes obstruction. This enlargement is due to the absence of normal enteric innervation resulting from arrested fetal development of the myenteric nervous system. The aganglionic section involves most commonly the rectosigmoid part of the colon; however it may affect the entire colon. Hirschsprung disease is the most common cause of intestinal obstruction in the neonate. Hirschsprung-associated enterocolitis occurs in 10% of patients and can be fatal.
- Symptoms:
 - Abdominal distension
 - Bilious emesis
 - Failure to pass a meconium stool within 24-48 hours after birth
 - Explosive stools on rectal exam
- Diagnostic tools/tests to perform:
 - Contrast enema
 - Rectal biopsy: demonstrating aganglionosis and hypertrophy of the nerve trunks.
- Other anomalies associations:
 - Down Syndrome
 - Intestinal Neuronal Dysplasia

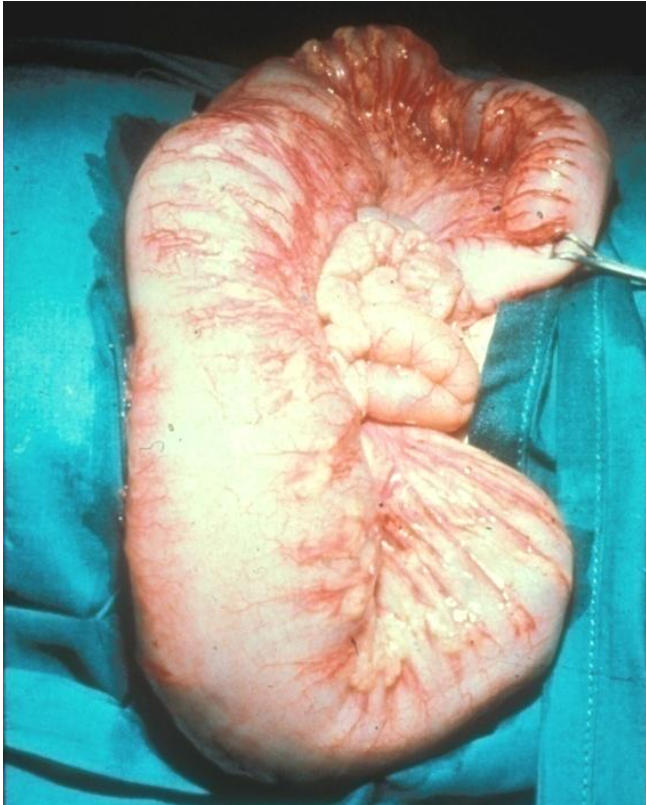

Figure 5.7⁴⁰ Hirschprung's disease

V.8. Congenital tracheoesophageal fistula

Refer to **V.I.** for more on description, symptoms, and other anomalies associations.

Chapter VI: Congenital malformations of the nervous system

In this section:

- VI. Introduction
- VI.1. Anencephaly
- VI.2. Arnold Chiari Syndrome
- VI.3. Encephalocele
- VI.4. Spina Bifida
- VI.5. Congenital hydrocephalus
- VI.6. Microcephaly

VI. Introduction: ^{11-12, 41, 44-58}

- Neural tube defects are birth defects of the brain and spinal cord.
- They occur when part of the neural tube, which forms the spine, spinal cord, skull and brain fails to close in utero during the first month of pregnancy.
- Spina bifida and anencephaly are the most common types of birth defects with an estimated 300,000 newborns affected worldwide (CDC, 2005).
- The etiology of neural tube defects is multifactorial. Metabolic defects, vitamin deficiencies, alcohol exposure, maternal insulin dependent diabetes, hyperthermia, obesity at conception, autosomal trisomies, and low serum folate concentrations have also been associated with these anomalies.
- Neural tube defects are often diagnosed in utero through maternal serum alpha-fetoprotein (AFP screening) at 16 to 20 weeks gestation and detailed fetal ultrasound at 16 to 22 weeks.

VI.1. Anencephaly:

- Description: Anencephaly is characterized by the total or partial absence of the cranial vault and the covering skin, the brain being missing or reduced to a small mass. Most cases are stillborn, although some infants have been reported to survive for a few hours or even a few days.
- Symptoms:
 - Blind
 - Deaf
 - Unconscious
 - Unable to feel pain
- Diagnostic tools/test to perform:
 - Prenatal diagnosis through maternal serum alpha-fetoprotein (MSAFP) test and ultrasound examination
 - Physical examination to rule out any associated malformation
 - Karyotype analysis
- Other anomalies associations: spina bifida, cleft lip and or palate, clubfoot and rarely omphalocele.

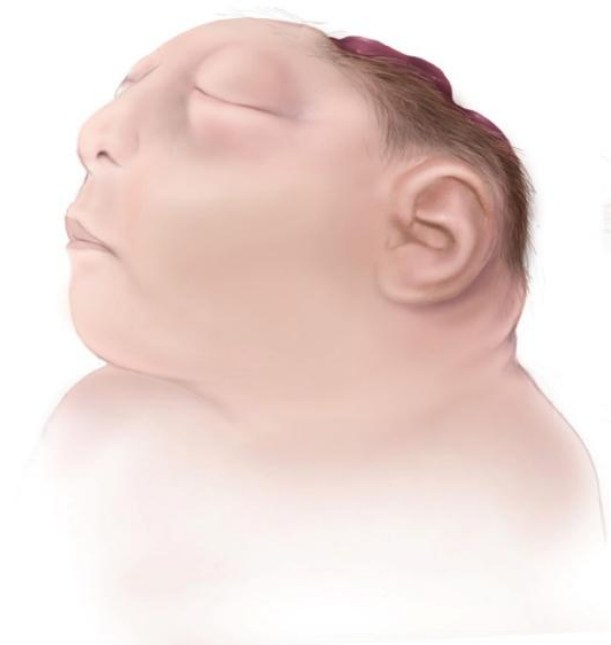

Figure 6.1⁴⁷ Anencephaly

VI.2. Arnold Chiari Syndrome

- Description: Arnold-Chiari Syndrome is a defect in the formation of the posterior fossa. Because the posterior fossa is small, the brain stem, cerebellum, or cerebellar tonsils are squeezed downward into the spinal cord region. The displaced tissues may obstruct the flow of cerebrospinal fluid. Although this malformation is present at birth, there may not be any symptoms of a problem until adulthood.
- Symptoms:
 - Rapid back-and-forth movement of the eyes
 - Muscle weakness
 - Facial pain
 - Hearing problems
 - Developmental delays
 - Poor feeding and swallowing;
 - Breathing problems
- Diagnostic tools/test to perform:
 - Physical examination to rule out any associated malformation
 - Computed tomography (CT) scan/ Magnetic resonance imaging (MRI) of the brain
 - Karyotype analysis
- Other anomalies associations:
 - Hydrocephalus
 - Spina bifida
 - Syringomyelia (a disorder in which a cyst or cavity forms within the spinal cord)

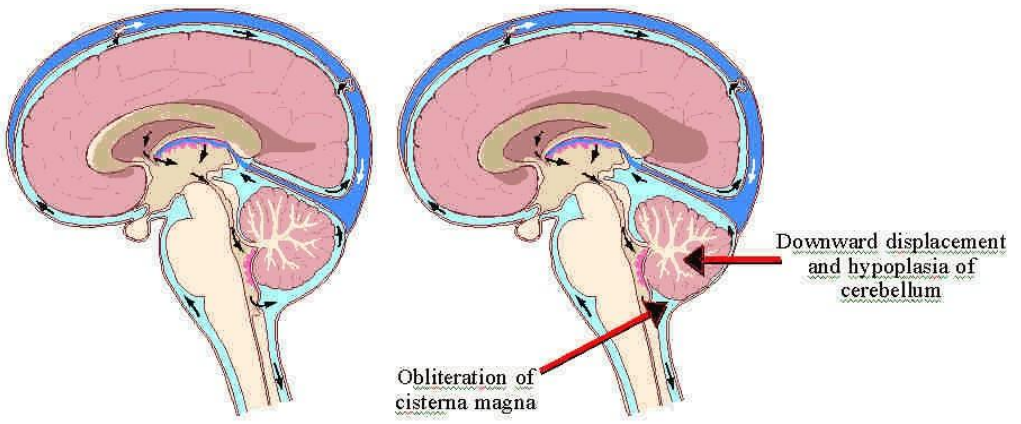


Figure 6.2 Arnold Chiari syndrome

VI.3. Encephalocele:

- Description: Encephalocele (or cranium bifidum) is a neural tube defect characterized by sac-like protrusions of the brain and the membranes that cover it through openings in the skull. These defects are caused by failure of the neural tube to close completely during fetal development.
- Symptoms:
 - Hydrocephalus
 - spastic quadriplegia (paralysis of the arms and legs)
 - Microcephaly (abnormally small head)
 - Ataxia (uncoordinated movement of the voluntary muscles, such as those involved in walking and reaching)
 - Developmental delay
 - Vision problems
 - Mental and growth retardation
 - Seizures
- Diagnostic tools/test to perform:
 - Prenatal diagnosis through maternal serum alpha-fetoprotein (MSAFP) test ultrasound examination
 - Physical examination to rule out any associated malformation
 - Computed tomography (CT) scan/ Magnetic resonance imaging (MRI) of the brain
 - Karyotype analysis
- Other anomalies associations:
 - Hydrocephalus
 - Microcephaly
 - Growth retardation
 - Meckel Gruber Syndrome
 - Deformities of Tentorium
 - Complete/partial agenesis of corpus callosum
 - Cerebral dysgenesis

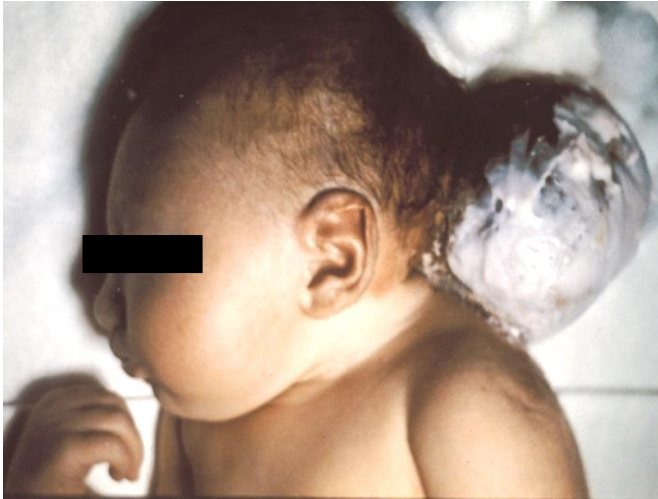

Figure 6.3a¹² Encephalocele

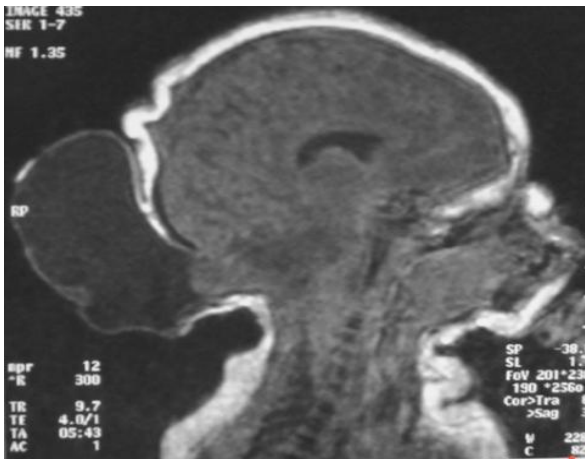


Figure 6.3b⁵⁹ Encephalocele (MRI)

VI.4.Spina bifida

- Description: Spina bifida is a general term used to describe a defect of the spine caused by a failure of the vertebrae to close. The disorder is most often located in the lumbar or sacral portion of the spine, and affects 2 or 3 vertebrae, although sometimes more. Forms of spina bifida include:
 - Myelomeningocele: Protrusion of the meninges (three layers of membranes covering the brain and spinal cord) and the spinal cord through an opening in the vertebral column
 - Meningocele: Protrusion of the meninges through a defect in the skull or spinal column forming a cyst filled with cerebrospinal fluid
 - Hydromeningocele: A fluid-filled protrusion of the spinal cord through a defect in the skull or vertebral column
 - Myelocele: Protrusion of the spinal cord through a defect in the vertebral arch.
 - Rachischisis: Embryologic failure of fusion of vertebral arches and neural tube with consequent exposure of neural tissue at the surface
 - Syringomyelocele: A form of spina bifida in which the fluid of the syrinx in the spinal cord is increased, expanding the cord tissue into a thin-walled sac that in turn expands through the vertebral defect.
- Symptoms:
 - Hydrocephalus
 - Abnormal tuft of hair, a collection of fat, a small dimple or a birthmark on the newborn's skin above the spinal defect may occur
- Diagnostic tools/test to perform:
 - Prenatal diagnosis through maternal serum alpha-fetoprotein (MSAFP) test and ultrasound examination of the fetal spine.
 - Physical examination to rule out any associated malformation
 - Ultrasound examination of the spine
 - Kayotype analysis
- Other anomalies associations: Hydrocephalus, Chiari II malformation.

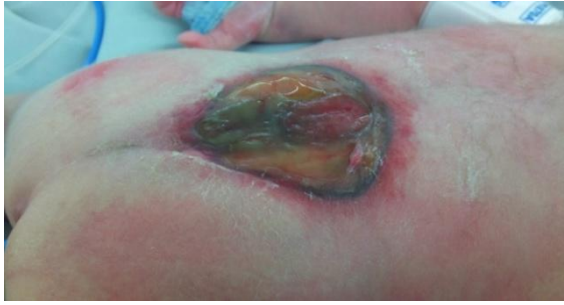

Figure 6.4a¹¹ Spina bifida

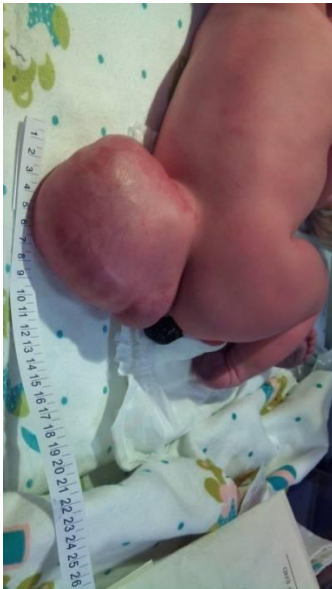

Figure 6.4b¹¹ Closed myelomeningocele

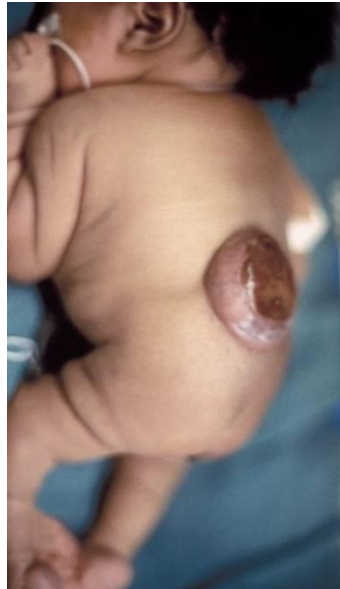

Figure 6.4c¹² Open myelomeningocele

VI.5. Congenital hydrocephalus:

- Description: Congenital hydrocephalus is a buildup of excess cerebrospinal fluid (CSF) within the brain that is present at birth. The excess fluid can increase pressure in the baby's brain, possibly resulting in brain damage and loss of mental and physical abilities. Prompt diagnosis and treatment is important to help limit serious long-term problems.
- Symptoms:
 - An abnormally large head
 - A characteristic fixed downward gaze with whites of the eyes showing above the iris
- Diagnostic tools/test to perform:
 - Prenatal diagnosis through ultrasound examination
 - Physical examination to rule out any associated malformation
 - Computed tomography (CT) scan/ Magnetic resonance imaging (MRI) of the brain
 - Karyotype analysis
- Other anomalies associations:
 - Neural tube defects
 - Arnold Chiari
 - Dandy-walker syndrome

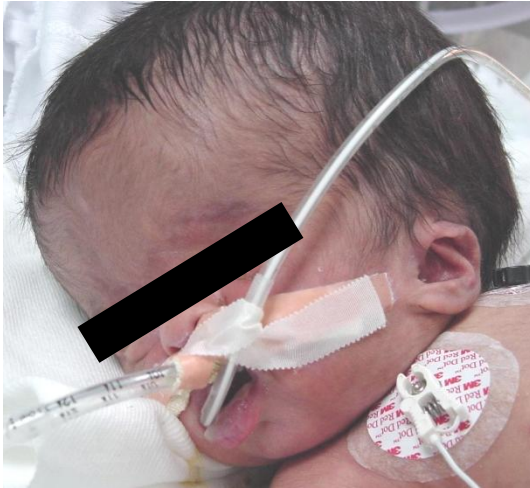

Figure 6.5a⁵⁹ Hydrocephalus

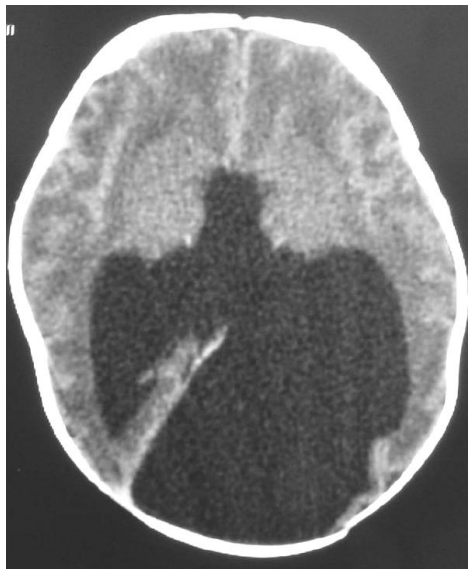


Figure 6.5b⁵⁹ Hydrocephalus (CT Scan)

VI.6. Microcephaly:

- Description:

- A minor neurological malformation, in which the head circumference is smaller than normal, based on standardized charts for the age and gender.
- May be due to malfunction in the brain development secondary to conditions that affect brain growth. These include:
 - Congenital infections
 - Genetic disorders
 - Severe malnutrition
- Includes hydromicrocephaly (microcephaly with increase in cerebrospinal fluid) and micrencephalon (an abnormally small brain)

- Associated Symptoms:

Mostly dependant of the underlying condition and can range from minor disabilities to severe ones including:

- Mental retardation
- Delayed motor functions and speech
- Facial distortions with large ears
- Visual impairment
- Dwarfism or short stature
- Hyperactivity
- Seizures
- Poor feeding

- Diagnosis:

- By prenatal ultrasound in some cases during the third trimester
- By physical examination at birth or later during infancy

- Most common Associated Syndromes:
 - Trisomy 21 (Down syndrome)
 - Trisomy 13 (Patau Syndrome)
 - Trisomy 18 (Edwards Syndrome)
 - Cornelia de Lange syndrome
 - Cri du chat syndrome (5p deletion)
 - Smith-Lemli-Opitz syndrome
 - Rubinstein-Taybi syndrome
 - Seckel syndrome

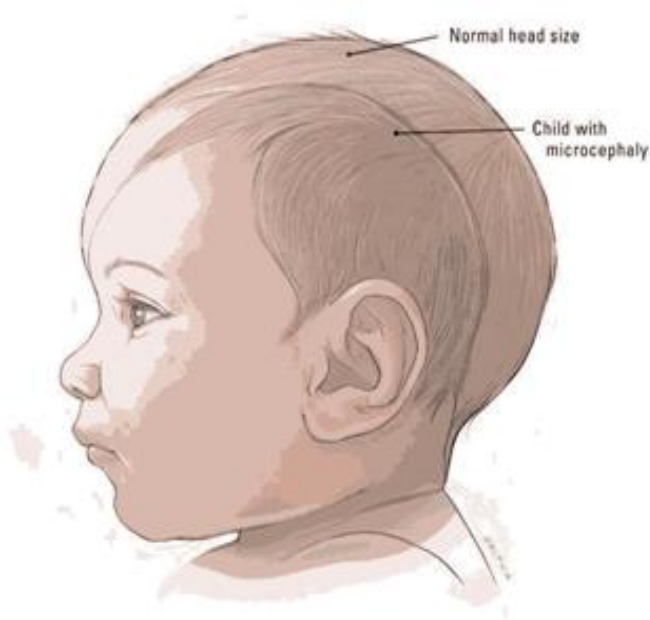

Figure 6.6 Microcephaly

Chapter VII: Congenital malformations of the urinary system and genital organs

In this section:

- VII. Introduction
- VII.1. Hypospadias
- VII.2. Renal agenesis and other reduction defects of kidney
- VII.3. Indeterminate sex, unspecified
- VII.4. Cystic Kidney Disease
- VII.5. Congenital hydronephrosis

VII. Introduction: ^{2, 11, 61-68}

- The urinary and genital systems are developmentally and anatomically closely associated. Defects in one system can be associated with defects in the other.
- Prevalence of urogenital malformations has a wide range: 1/10,000 in polycystic kidney recessive disease to 3/1,000 in bilateral renal agenesis.
- There may be minor or major defects with organ dysfunction.
- The most common urogenital defects include:
 - Renal agenesis (Potter's sequence)
 - Hydronephrosis
 - Polycystic kidney disease
 - Multicystic kidneys
 - Bladder exstrophy
 - Epispadias and hypospadias
 - Ambiguous genitalia.
- Prenatal diagnosis by fetal ultrasound is possible for many defects.
- These anomalies are often associated with other malformations including:
 - Polydactyly and syndactyly for renal malformations
 - Chromosomal abnormalities for genital malformations.

VII.1. Hypospadias

- Description:
 - Hypospadias refers to the abnormal opening of the urethra or the urinary meatus (urinary outlet)
 - Hypospadias occurs in about 1/500 live male births
 - The urinary sphincters are not defective therefore incontinence does not occur.
 - Severe hypospadias is more likely to be associated with chordee or with undescended testes (cryptorchidism),
 - Chordee, or ventral curvature of the penile shaft is the condition by which the phallus is incompletely separated from the perineum or is still tethered by the shortened ventral penile skin (cutaneous chordee) or in more severe cases underdevelopment of the ventral corpus spongiosum and corporal cavernosa (fibrous chordee).

- Symptoms:
 - The site of the urethral meatus may be anywhere between the proximal glans penis and the perineum (area between the genitals and the anus).
 - Hypospadias is classified depending on the location of the meatus:
 - Glanular
 - Coronal
 - Distal or midshaft
 - Penoscrotal
 - Scrotal
 - Perineal
 - 75% of Hypospadias are proximal or coronal
 - Hypospadias is diagnosed based on the abnormal appearance of the glans penis (see illustrations)
 - The foreskin can be incomplete extending only around the top of the penis

- Diagnostic tools/test to perform:
 - Physical examination
 - Imaging may be needed to look for other congenital defects.
 - Hypospadias may need surgical correction between 6 and 12 months for cosmetic or reproductive reasons.

- Other anomalies associations:
 - Undescended testis
 - Inguinal hernia
 - Ambiguous genitalia should be suspected if hypospadias is associated with bilateral undescended testis, micropenis, or a bifid scrotum.

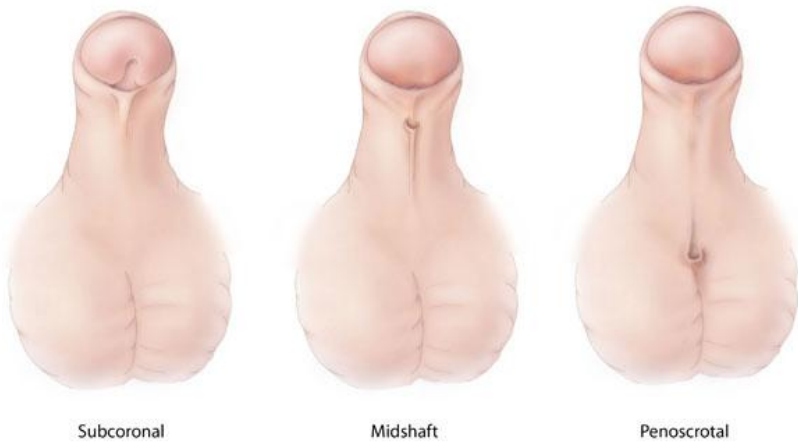


Figure 7.1⁶¹ Hypospadias

VII.2. Renal Agenesis and other reduction defects of kidney

- Description:
 - Renal agenesis is a congenital malformation characterized by complete absence of kidneys unilaterally or bilaterally, or by a severely dysplastic kidneys.
 - Potter syndrome is the association of renal agenesis with pulmonary hypoplasia (underdeveloped lungs), and specific facial features. “Potter's facies” reflects the physical appearances of a fetus compressed in utero due to oligohydramnios)
- Symptoms:
 - Widely separated eyes with epicanthal folds, broad nasal bridge, low set ears, and receding chin.
 - Absence of urine output
 - Severe respiratory distress
- Diagnostic tools/test to perform:
 - Prenatal ultrasound may show oligohydramnions, absence of fetal kidneys, or severely abnormal kidneys
- Other anomalies associations:
 - VACTERL (Vertebral anomalies, Anal atresia, Cardiac defects, TE fistula [tracheoesophageal fistula], Renal defects, Limb defects)
 - Isolated anomalies of:
 - Cardiovascular
 - Skeletal
 - Central nervous systems
 - Caudal dysplasia syndrome (hypoplastic lower extremities, caudal vertebrae, sacrum, neural tube, and urogenital organs)
 - Sirenomelia (single lower extremity, absent sacrum, urogenital anomalies, and imperforate anus).

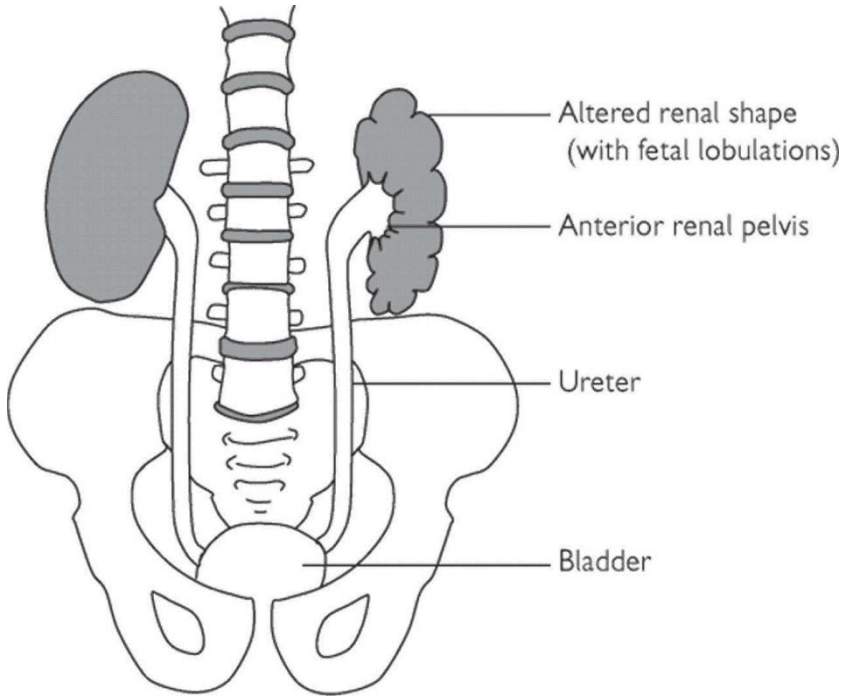


Figure 7.2 Renal agenesis

VII.3.Indeterminate Sex, unspecified

- Description:

- The infant's genitalia at birth is incompletely developed and appears ambiguous and does not readily allow for sex determination.
- The newborn may have features of both sexes.
- This constitutes a true social emergency
- Gender assignment should be delayed until all the information, including karyotype, hormonal evaluation and organ imaging is obtained.

- Symptoms:

- Female pseudohermaphroditism: (karyotype 46 XX):
 - the most common cause is congenital adrenal hyperplasia secondary to 21 hydroxylase deficiency
 - There is varying degrees of masculinization of the genitalia due to increased testosterone and dihydrotestosterone levels
 - Anomaly can range from an enlarged clitoris to a phallus or small penis with severe hypospadias and fused empty scrotum.
 - The urethral opening can be anywhere along, above, or below the surface of the clitoris/phallus.
- Male (XY):
 - A small penis (less than 2-3 centimeters or 0.8-1.2 inches) that resembles an enlarged clitoris (which could be normal in a newborn female).
 - The urethral opening may be anywhere along, above, or below the penis;
 - There may be a small scrotum with any degree of separation, making it resemble labia majora.
 - Undescended testicles are commonly seen with ambiguous genitalia.

- Diagnostic tools/test to perform:

- Buccal smear (if available)
- Chromosomal analysis (Karyotype)
- Laboratory tests: serum electrolytes, urinary steroids, 17-hydroxyprogesterone.
- Abdominal or pelvic ultrasound, looking for gonads and internal genital structures (such as undescended testes, tubes, uterus, ovaries).

- Other anomalies associations:

Associated symptoms are uncommon but include omphalocele, hypospadias, crossed renal ectopia and vesicoureteric reflux.

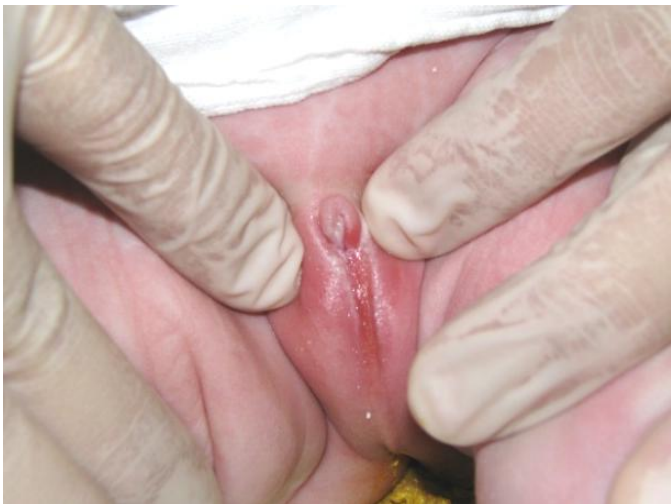

Figure 7.3¹¹ Ambiguous Genitalia

VII.4. Cystic kidney disease

- Description: Cystic kidney disease describes several conditions in which fluid-filled cysts form in the kidneys. Cysts generally develop in weak segments of the tubules that carry urine from the glomeruli. The cyst's growth displaces healthy kidney tissue. There are 2 forms of cystic kidney disease:
 - Autosomal **recessive** which is a rare inherited disease, referred to as “**Infantile polycystic Kidney Disease**”
 - Autosomal **dominant** cystic disease which is the most common inherited form, referred to as “**Adult polycystic Kidney Disease**”. Prenatal or neonatal presentation is uncommon.
- Symptoms for infantile or autosomal recessive polycystic kidney disease:
 - Oligohydramnios
 - Pulmonary hypoplasia
 - Massively enlarged kidneys
 - Liver involvement: dilated bile ductules
 - Severe respiratory distress at birth
 - Severe renal function impairment
- Diagnostic tools/test to perform:
 - Abdominal Ultrasonography
- Other anomalies associations:
 - Asymptomatic cysts in liver/pancreas/ testes
 - Heart valve abnormalities (especially mitral valve prolapsed)

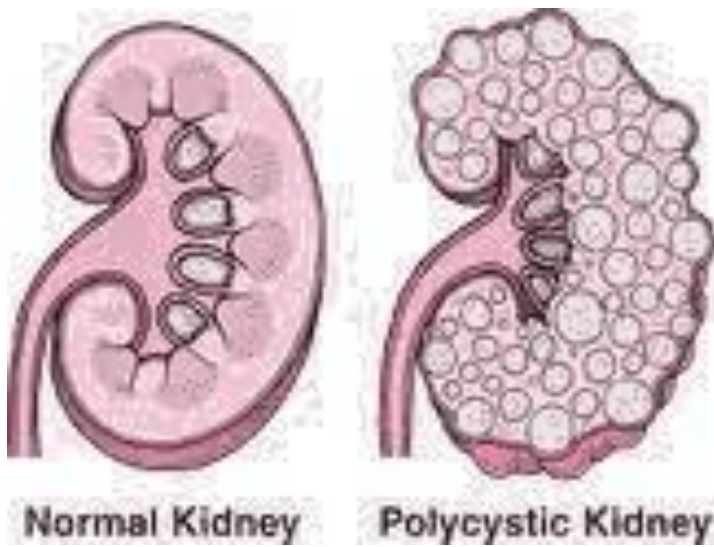


Figure 7.4 Polycystic kidney disease

VII.5. Congenital hydronephrosis

- Definition:

- In other terms "water inside the kidney"
- Refers to distension and dilation of the renal pelvis and calyces.
- Caused by obstruction of the free flow of urine from the kidney.
- If untreated, it leads to progressive atrophy of the kidney. The accumulation of excess urine in the kidney may be caused by either blockage to the urinary flow (kidney obstruction) or leak backward from the distal urinary system (vesico-uretral reflux).

- Symptoms:

- Most conditions are diagnosed on the prenatal ultrasound (54-56).
- Sudden onset hydronephrosis causing intense pain is not usually seen at birth.
- The most feared complication is pyelonephritis and complete obstruction which can lead to kidney failure.

- Associated anomalies:

Other congenital genitourinary disorders that may be diagnosed prenatally and may be associated with hydronephrosis are:

- Bladder exstrophy
- Renal tumors
- Cloacal anomalies
- Intersex states
- Hypospadias

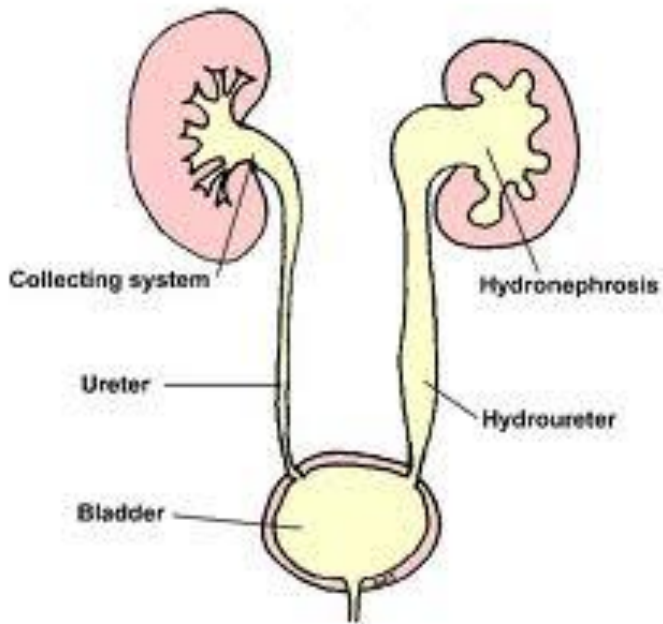


Figure 7.5 Hydronephrosis

Chapter VIII: Congenital malformations of the respiratory system

In this section:

- VIII. Introduction
- VIII.1. Choanal Atresia
- VIII.2. Hypoplasia and dysplasia of lung

VIII. Introduction:^{14, 69}

- Congenital anomalies of the respiratory system include a wide variety of malformations of the upper and lower respiratory tract.

- These include:
 - Choanal atresia
 - Tracheal atresia
 - Congenital bronchopulmonary malformations (congenital lobar emphysema, pulmonary sequestration, cystic adenomatoid malformation and bronchogenic cysts)
 - Misalignment of pulmonary veins with alveolar capillary dysplasia
 - Surfactant protein B deficiency
 - Congenital pulmonary lymphangiectasia
 - Pulmonary arteriovenous fistula
 - Mediastinal masses and
 - Pulmonary hypoplasia.

- Most of these malformations present early after birth with respiratory distress; some are lethal and not compatible with life, others may not present until after the neonatal period and require a high index of suspicion and sophisticated diagnostic imaging.

VIII.1. Choanal Atresia

- Description:
 - Most common congenital anomaly of the nose
 - Frequency about 1/7.000 live births
 - Consists of a block (or septum) between the nose and the pharynx either on one side or both sides.
 - This septum is most of the time (90%) of bony structure, 10% of the time it is membranous or soft tissue.
 - Most cases are combination of bony and membranous atresia
 - 50% of affected infants have other congenital abnormalities
 - Bilateral Choanal atresia is a surgical emergency.
- Symptoms:
 - May be asymptomatic (if atresia is on one side)
 - May present with respiratory distress if atresia is on both sides and baby is unable to breathe from her mouth
 - Cyanosis especially when sucking, infant becomes pink when they cry
 - Inability to suck and breathe at same time leads to cyanosis with feeding
 - Placement of an oral airway to maintain the mouth open will relieve symptoms.
- Diagnostic :
 - Failure to pass a firm small catheter through each nostril 3-4cm into the nasopharynx
 - Can be seen directly with fiberoptic rhinoscopy
 - Best seen by high resolution CT scan.
- Other associated anomalies:
 - CHARGE syndrome: coloboma, heart disease, atresia choanae, retarded growth and development or CNS anomalies or both, genital anomalies and ear anomalies or deafness.

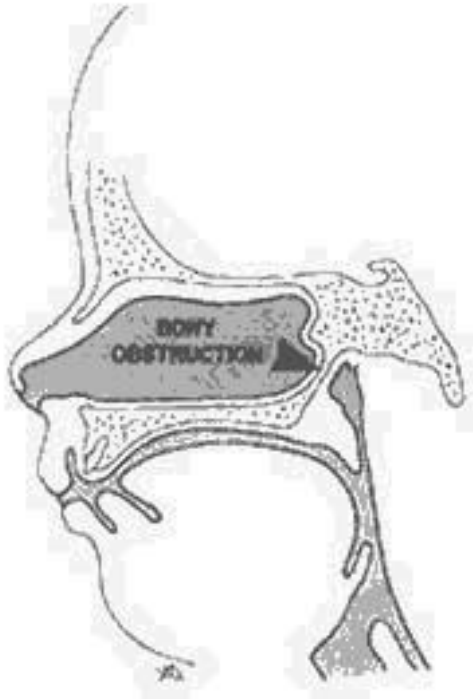


Figure 8.1 Choanal atresia

VIII.2. Hypoplasia and dysplasia of lung

- Description:

This condition is secondary to other intrauterine disorders that produce an impairment of normal lung development leading to underdeveloped small lungs. The hypoplasia or dysplasia involves a decrease in the number of alveoli and airway generations, in addition to abnormal airway development.

- Symptoms:

- Severe respiratory insufficiency with:
 - hypoxemia
 - respiratory and metabolic acidosis
- Persistent pulmonary hypertension
- Pneumothorax in severe cases

- Diagnostics:

- Chest X-ray
- CT-Scan

- Conditions associated with pulmonary hypoplasia:

- Deformities of the thoracic spine and rib cage
- Pleural effusion from hydrops fetalis
- Cystic adenomatoid malformation
- Congenital diaphragmatic hernia
- Any condition that produce oligohydramnios:
 - fetal renal insufficiency
 - prolonged premature rupture of membranes especially before 20 weeks of gestation.

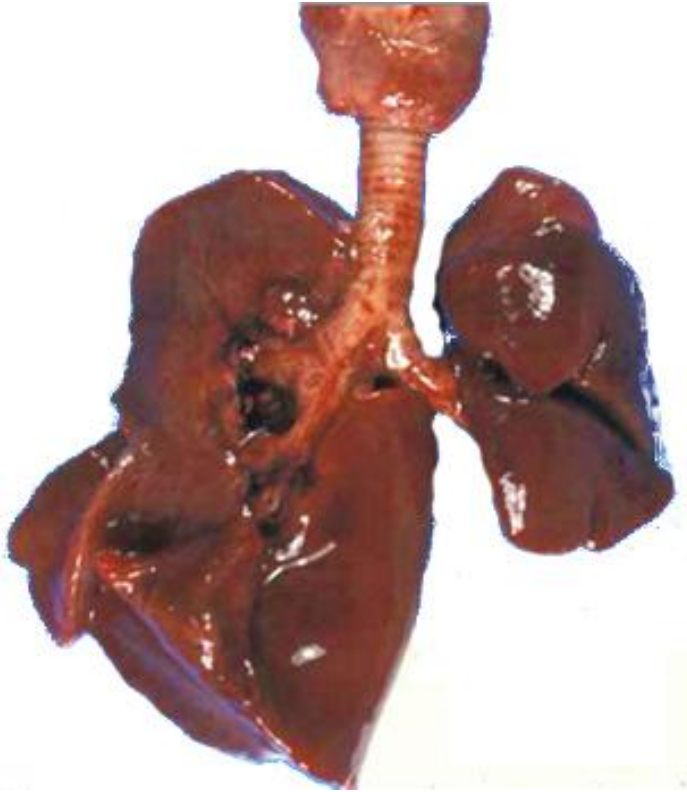


Figure 8.2 Hypoplasia of lung

Chapter IX: Congenital malformations of eye, ear, face and neck

In this section:

- IX. Introduction
- IX.1. Anophthalmos, microphthalmos and macrophthalmos.
- IX.2. Congenital Cataract
- IX.3. Webbing of neck
- IX.4. Microtia/ Anotia

IX. Introduction: ⁷⁰⁻⁸¹

- Congenital malformations of eye, ear, face and neck exclude cleft lip and/or cleft palate, congenital malformation of the cervical spine, larynx, lip necrotizing enterocolitis (NEC), nose, parathyroid gland, and thyroid gland.
- The most common defects include:
 - Anophthalmos, microphthalmos and macropthalmos
 - Congenital cataract
 - Webbing neck
 - Microtia/Anotia
- The causes of the majority of cases of eye, ear, face, and neck anomalies are unknown. Some data on congenital eye anomalies indicates that hereditary factors, infection (such as Rubella during pregnancy) and metabolic disorders are the main risk factors.
- The prevalence rate of these malformations ranges between the different types of malformations. Data on congenital eye malformations indicates a prevalence rate of 7.5 per 10,000 in France. The prevalence of Anophthalmos, microphthalmos and macropthalmos ranges around between 11.8 and 18 per 100,000 cases. The prevalence of congenital cataract is unknown internationally and it is estimated to be 1.2 – 6 cases per 10,000 in the United States. Data from birth defects surveillance programs around the world showed an overall prevalence for microtia and anotia of 1.55 and 0.36 per 10,000 births respectively.

IX.1. Anophthalmos, microphthalmos and macrophthalmos

- Description:
 - Anophthalmos: the absence of visible sign of a globe or ocular tissue.
 - Microphthalmos: “an abnormally small eye.”
Reference measurements for microphthalmos (axial length 16 mm at birth, 19 mm at 12 months of age and corneal diameter at birth 10 mm) are provided as a guide only, not as diagnostic criteria.
 - Macrophthalmos: an abnormally large size of the eyes. It is characterized by bilateral congenital enlargement of the cornea and anterior segment of the globe.

- Diagnosis:
 - Computed tomography (CT) scan
 - Magnetic resonance imagings (MRI) scan.

- Associated anomalies:
 - Congenital cataracts
 - Congenital cystic eye
 - Micro cornea
 - Cleft lip/palate
 - Scalp defect

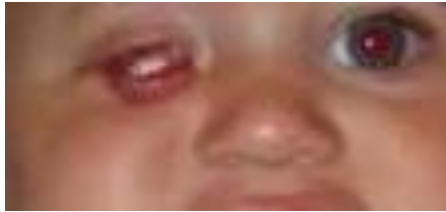

Figure 9.1a Anophthalmos



Figure 9.1b Microphthalmos

IX.2. Congenital Cataract

- Description:
 - It is a clouding of the normally clear and transparent lens inside the eye. It can cause unclear vision and if not treated, will lead to amblyopia (cortical blindness) in the affected eye.
 - Is present at birth; and is known as "infantile cataract" if it develops in the first six months after birth.
 - It can affect one eye (unilateral cataract) or both eyes (bilateral cataracts). Most children with unilateral cataract have good vision in the other eye.
 - It can come in different types based on the location of the lens. A cataract located towards the center of the lens is more likely to affect vision and visual development.

- Symptoms:
 - Cloudiness of the lens that looks like a white spot in an otherwise normally dark pupil
 - Failure of an infant to show visual awareness of the world around him or her (if cataracts present in both eyes)
 - Unusual rapid eye movements

- Diagnosis:
 - Screening of all infants within the first 24-28 hours after birth should be done as part of the regular physical assessment.
 - Infants are usually checked again by a health visitor around six weeks of age. If a parent is concerned at any stage that their baby is not seeing normally, they should discuss this with their family doctor.
 - If the obstetrician or hospital doctor suspects that a child has a congenital cataract they, will arrange a full examination of the eye and lens.



Figure 9.2: Congenital Cataract

IX.3. Webbing of neck

- Definition:
 - Also called a webbed neck or pterygium colli, is marked by a fold of skin on each side of the neck. The folds often reach from behind the ear to the shoulders.
 - Some children are born with neck webbing and it stays with them through adulthood.

- Symptoms:
 - Neck webbing is loose in newborns, often appearing as loose flaps of skin.
 - As the body grows, the neck webbing tightens and stretches. Older children and adults who retain their webbed necks often appear to have shortened necks or no neck at all.

- Associated anomalies:
 - Turner syndrome (46XO)
 - Noonan syndrome

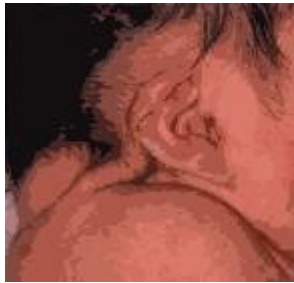

Figure 9.3 Webbing of the neck

IX.4. Microtia/ Anotia

- Description:
 - Minor malformation characterized by an incompletely formed ear or in severe cases absence of the outer ear (called anotia).
 - One ear is affected in 80% of the cases.
 - In most cases, only 40% of the hearing is reduced in the affected ear.
- Diagnosis:
 - Fetal ultrasound in some cases.
 - Physical examination at birth
- Associated anomalies:
 - Microsomia
 - Treacher Collins syndrome should be suspected, if both ears are involved.

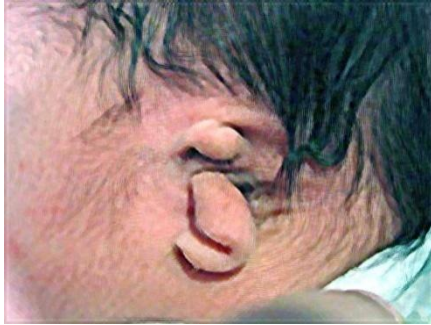

Figure 9.4a Microtia

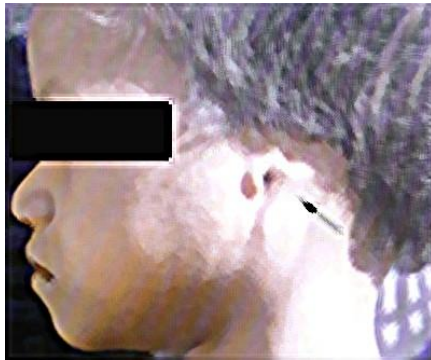

Figure 9.4b Anotia

References:

1. Christianson A, Howson C, Modell B. 2006. Global report on birth defects the hidden toll of dying and disabled children. March of Dimes birth defects foundation, White plains, New York
2. Clark, David A. contributors Thompson, Jeffery and Barkemeyer Brain. 2000. Atlas of Neonatology, W.B. Saunders Company, Philadelphia ISBN: 0721676367
3. Rimoin DL, Connor JM, Pyeritz RE, Korf BR (Editors). 2002. Emery and Rimoin's Principles and Practice of Medical Genetics. Churchill Livingstone, London, Edinburgh, New York, Sydney, Toronto.
4. Seashore MR, Wappner RS. 1996. Genetics in Primary Care & Clinical Medicine. Prentice-Hall International Inc. New York.
5. Clinical Synopsis of Moss and Adams' Heart Disease in Infants, Children, and Adolescents. Emmanouilides et al., Lippincott Williams and Wilkins, 1998. ISBN: 0683180037
6. Courtesy of Dr. Najji Abou Chebel
7. American College of Obstetricians and Gynecologists (ACOG). Prenatal Diagnosis of Fetal Chromosomal Abnormalities. ACOG Practice Bulletin, volume 27, May 2001.
8. Carey, J.C. Chromosomal Disorders, in Rudolph, C.D, and Rudolph, A.M. (eds.), Rudolph's Pediatrics, 21st Edition, New York, McGraw-Hill Medical Publishing Division, 2003, pages 731-741.
9. National Institutes of Health (NIH). Genetics Home Reference. Published 5/06, <http://ghr.nlm.nih.gov/>
10. Support Organization for Trisomy 18, 13, and Related Disorders (SOFT). Trisomy 18 Facts, Trisomy 13 Facts. www.trisomy.org/ (Last accessed May 20, 2010)
11. Courtesy of Dr. Lama Charafeddine
12. Courtesy of Dr. Nadia Sakati
13. <http://www.google.com.lb/imgres/barlow+maneuver+and+ortolani+maneuver> (last accessed May 02, 2012)

14. Better Health Channel (2010) Potter's Syndrome (hyperlink) http://www.betterhealth.vic.gov.au/bhcv2/bhcarticles.nsf/pages/Birth_defects_of_the_urinary_system (last accessed May 20, 2010)
15. Encyclopedia of children's health (2010) Clubfoot (hyperlink) <http://www.healthofchildren.com/C/Clubfoot.html> (last accessed May 20, 2010)
16. Encyclopedia of children's health (2010) Congenital Hip Dysplasia (hyperlink) <http://www.healthofchildren.com/C/Congenital-Hip-Dysplasia.html> (last accessed May 20, 2010)
17. Storer, S. & Skaggs, D. (2006). Developmental dysplasia of the hip. *American Family Physician*, 74:1310-6. doi: www.aafp.org/afp/20061015/1310.html (last accessed May 20, 2010)
18. New York Times with reference from ADAM (2010) Developmental hip dysplasia (hyperlink) <http://health.nytimes.com/health/guides/disease/developmental-dysplasia-of-the-hip/overview.html> (last accessed May 20, 2010)
19. New York Times reference from ADAM. (hyperlink) <http://health.nytimes.com/health/guides/disease/diaphragmatic-hernia/overview.html> (last accessed May 20, 2010)
20. Children's Hospital of Wisconsin. (2010) Diaphragmatic Hernia (hyperlink) <http://www.chw.org/display/PPF/DocID/34373/Nav/1/router.asp> (last accessed May 20, 2010)
21. Tomoaki, T; Tooru, U; Koji, N; Koji, M.; Sachiyo, S. (2006). Cardiac Anomalies Associated with Congenital Diaphragmatic Hernia. *Japanese Journal of Pediatric Surgery*, 38, 163-169. doi: <http://sciencelinks.jp/j-east/article/200608/000020060806A0182838.php> (last accessed May 20, 2010)
22. Nicola Lewis for e-medicine (2010) Diaphragmatic Hernia (hyperlink) <http://emedicine.medscape.com/article/934824-overview> (last accessed May 20, 2010)

23. CDC. (2010) Gastroschisis (hyperlink) <http://www.cdc.gov/ncbddd/birthdefects/Gastroschisis.htm> (last accessed May 20, 2010)
24. New York Times reference from ADAM (2010) Gastroschisis (hyperlink) <http://health.nytimes.com/health/guides/disease/gastroschisis/overview.html> (last accessed May 20, 2010)
25. Chabra, S. & Gleason Ch. (2010). Gastroschisis: Embryology, Pathogenesis, Epidemiology. *American Academy of Pediatrics*, 6(11), e493. doi: <http://neoreviews.aappublications.org/cgi/content/extract/6/11/e493> (last accessed May 20, 2010)
26. Khan, A.N. (2010). Gastroschisis for e-medicine <http://emedicine.medscape.com/article/403800-overview> (last accessed May 20, 2010)
27. Encyclopedia of children's health Abdominal Wall Defects (hyperlink) <http://www.healthofchildren.com/A/Abdominal-Wall-Defects.html> (last accessed May 20, 2010)
28. Encyclopedia of surgery (2010) Omphalocele (hyperlink) <http://www.surgeryencyclopedia.com/La-Pa/Omphalocele-Repair.html> (last accessed May 20, 2010)
29. The children's hospital of Philadelphia (2010) Omphalocele (hyperlink) <http://www.chop.edu/consumer/jsp/division/generic.jsp?id=81171> (last accessed May 20, 2010)
30. Wikipedia encyclopedia (2010) Prune Belly Syndrome (hyperlink) http://en.wikipedia.org/wiki/Prune_belly_syndrome (last accessed May 20, 2010)
31. Baskin, Laurence S. and Kogna, Barry A. Handbook of Pediatric Urology (second ed.), Lippincot Williams & Wilkins Philadelphia (2005) ISBN: 0781751624, (pp.159-163)
32. Medline plus (2010) Prune Belly Syndrome (hyperlink) <http://www.nlm.nih.gov/medlineplus/ency/article/001269.htm> (last accessed May 20, 2010)

33. E-Medicine (2010) Prune Belly Syndrome (hyperlink) <http://emedicine.medscape.com/article/412372-overview> (last accessed May 20, 2010)
34. Aliyu, M.H; Salihu, H.M; Kouam, L. (2003). Eagle-Barrett Syndrome: Occurrence and outcomes. East African Medical Journal, 80(11).doi: <http://ajol.info/index.php/eamj/article/viewFile/8771/1890> (last accessed May 20, 2010)
35. <http://en.wikipedia.org/wiki/Polydactyly> (last accessed May 02, 2012)
36. <http://www.cdc.gov/ncbddd/birthdefects/UL-LimbReductionDefects.html> (last accessed May 02, 2012)
37. <http://www.wales.nhs.uk/sites3/Documents/416/Limb%20reduction%20defects.pdf> (last accessed May 02, 2012)
38. <http://en.wikipedia.org/wiki/Syndactyly>
39. <http://www.childrenshospital.org/az/Site1036/mainpageS1036P0.html> (last accessed May 02, 2012)
40. Courtesy of Dr. Maher Soubra
41. Richard Martin, Avroy Fanaroff and Michele Walsh, Editors, Fanaroff and Martin Neonatal–Perinatal Medicine, Diseases of the Fetus and Infant (eighth ed.), Elsevier Mosby, Philadelphia (2006) ISBN: 0323029663, 1819 pp. (in 2 volumes)
42. Rx Med General Illness Information- anal fistula (hyperlink) http://www.rxmed.com/b.main/b1.illness/b1.1.illnesses/anal_fistula.html (Last accessed May 19, 2010)
43. Wikipedia (2010) Meckel's diverticulum (hyperlink) http://en.wikipedia.org/wiki/Meckel%27s_diverticulum (last accessed May 19, 2010)
44. Mayo Foundation for Medical Education and Research (2010) Spina bifida (hyperlink) <http://www.mayoclinic.com/health/spina-bifida/DS00417/DSECTION=symptoms> (last accessed May 20, 2010)

45. Wikipedia the free encyclopedia (2010) Spina bifida (hyperlink) http://en.wikipedia.org/wiki/Spina_bifida (last accessed May 20, 2010)
46. National institution of neurological disorders and stroke – National Institutes of Health (2010) encephaloceles (hyperlink) <http://www.ninds.nih.gov/disorders/encephaloceles/encephaloceles.htm> (last accessed May 20, 2010)
47. Perinatal institute for maternal and child health (2010) Anencephaly (hyperlink) <http://www.perinatal.nhs.uk/car/anomaly/cns/anencephaly.htm> (last accessed May 20, 2010)
48. Wikipedia the free encyclopedia (2010) Agenesis of the corpus callosum (hyperlink) http://en.wikipedia.org/wiki/Agenesis_of_the_corpus_callosum (last accessed May 20, 2010)
49. Wikipedia the free encyclopedia (2010) Arnold Chiari (hyperlink) http://en.wikipedia.org/wiki/Arnold-Chiari_malformation (last accessed May 20, 2010)
50. Health care. Net /Neurological disorders (2010) Arnold Chiari (hyperlink) <http://neurology.health-cares.net/arnold-chiari-malformation-symptoms.php> (last accessed May 20, 2010)
51. National institution of neurological disorders and stroke – National Institutes of Health (2010) Dandy walker (hyperlink) <http://www.ninds.nih.gov/disorders/dandywalker/dandywalker.htm> (last accessed May 20, 2010)
52. Cleveland clinic (2010) Dandy walker (hyperlink) http://my.clevelandclinic.org/disorders/dandy-walker_syndrome/hic_dandy-walker_syndrome.aspx (last accessed May 20, 2010)
53. Wikipedia the free encyclopedia (2010) Hydrocephalus (hyperlink) <http://en.wikipedia.org/wiki/Hydrocephalus> (last accessed May 20, 2010)

54. <http://www.nlm.nih.gov/medlineplus/ency/article/003272.htm> (last accessed May 02, 2012)
55. <http://health.nytimes.com/health/guides/symptoms/microcephaly/overview.html> (last accessed May 02, 2012)
56. <http://www.mayoclinic.com/health/microcephaly/DS01169/DSECTION=symptoms> (last accessed May 02, 2012)
57. <http://www.medicinenet.com/microcephaly/article.htm> (last accessed May 02, 2012)
58. http://my.clevelandclinic.org/disorders/microcephaly/hic_microcephaly.aspx (last accessed May 02, 2012)
59. Courtesy of Dr. Omar Dabbagh
60. Centers for disease control and prevention <http://www.cdc.gov/ncbddd/birthdefects/Anencephaly.html> (last accessed April 25, 2012)
61. Centers for disease control and prevention <http://www.cdc.gov/ncbddd/birthdefects/Hypospadias.html> (last accessed April 25, 2012)
62. Pediatric Health Channel (2008) Undescended Testicle (hypertlink) <http://www.pediatrichealthchannel.com/undescended-testicle/symptoms.shtml> (last accessed May 20, 2010)
63. eMedicine Pediatrics (2010) Cystic Kidney Disease (hyperlink) <http://emedicine.medscape.com/article/983281-overview> (last accessed May 20, 2010)
64. Merck Manual Profession (2007) Cystic Kidney Disease (hyperlink) <http://www.merck.com/mmpe/sec17/ch232/ch232f.html> (last accessed May 20, 2010)
65. University of California, San Francisco Hypospadias (hyperlink) http://www.ucsfhealth.org/childrens/medical_services/urology/hspadias/conditions/hypo/signs.html (last accessed May 20, 2010)
66. Wikipedia (2010) Hypospadias (hyperlink) <http://en.wikipedia.org/wiki/Hypospadias> (last accessed May 20, 2010)

67. Medline Plus (2010) Ambiguous genitalia and (hyperlink) <http://www.nlm.nih.gov/medlineplus/ency/article/003269.htm> (last accessed May 20, 2010)
68. Medline Plus (2010) Potter's Syndrome (hyperlink) <http://www.nlm.nih.gov/medlineplus/ency/article/001268.htm> (last accessed May 20, 2010)
69. Medline Plus (2010) Choanal Atresia (hyperlink) <http://www.nlm.nih.gov/medlineplus/ency/article/001642.htm> (last accessed May 20, 2010)
70. Shaheen P. et al. Anophthalmos, microphthalmos and coloboma in the United Kingdom: Clinical Features, Results of investigations, and early management. *ophtha*.2011.07.039
71. M. Erol Turaçlı, Oya Tekeli. Anterior megalophthalmos with pigmentary glaucoma. *Graefe's Arch Clin Exp Ophthalmol* 2005; 243: 1066-8.
72. CJ McLean, NK Ragge, RB Jones, JRO Collin. The management of orbital cysts associated with congenital microphthalmos and anaphthalmos. *Br J Ophthalmol* 2003; 87:860-863.
73. <http://www.ccakids.com/Syndrome/Microtia.PDF>
74. <http://www.childrenshospital.org/az/Site1298/mainpageS1298P1.html>
75. Wikisource (2011) ICD-10-CM (2010), Chapter 17 (Hyperlink) [http://en.wikisource.org/wiki/ICD-10-CM_\(2010\)/CHAPTER_17](http://en.wikisource.org/wiki/ICD-10-CM_(2010)/CHAPTER_17) (last accessed April 26, 2012).
76. Royal National Institute of Blind People (RNIB) (2011) Congenital Cataracts (hyperlink) http://www.rnib.org.uk/eyehealth/eyeconditions/conditionsac/Pages/congenital_cataracts.aspx (last accessed April 27, 2012)
77. <http://www.ncbi.nlm.nih.gov/pubmed/11853605>
78. <http://informahealthcare.com/doi/abs/10.3109/13816819209046487>
79. Shaheen P. Shah, S.P, Taylor, A.E, Sowden J. C, Nicola K. Ragge, N.K, Russell-Eggitt I., Rahi, J. S, & Gilbert, C. A. (2011). Anophthalmos, Microphthalmos, and Typical Coloboma in the United Kingdom: A Prospective Study of Incidence and Risk. *Investigative Ophthalmology & Visual Science*, 52 (1), 558 – 564. The incidence of congenital cataract is unknown internationally and it is estimated to be 1.2 – 6 cases per 10,000 in the United States

80. Mounir Bashour for e – medicine (2011) Congenital Cataract (hyperlink) <http://emedicine.medscape.com/article/1210837-overview#a0101> (last accessed April 27, 2012).
81. Luquetti, D. V., Leoncini, E., & Mastroiacovo, P. (2011). Microtia-Anotia: A Global Review of Prevalence Rates. *Birth Defects Research (Part A)* 91:813_822
82. Wexler D, Grosser DM, Kile TA. Bunion and bunionette. In: Frontera WR, Silver JK, eds. *Essentials of Physical Medicine and Rehabilitation*. 2nd ed. Philadelphia, Pa: Saunders Elsevier; 2008:chap 76.